



# Stroke


Yee Mon Htun

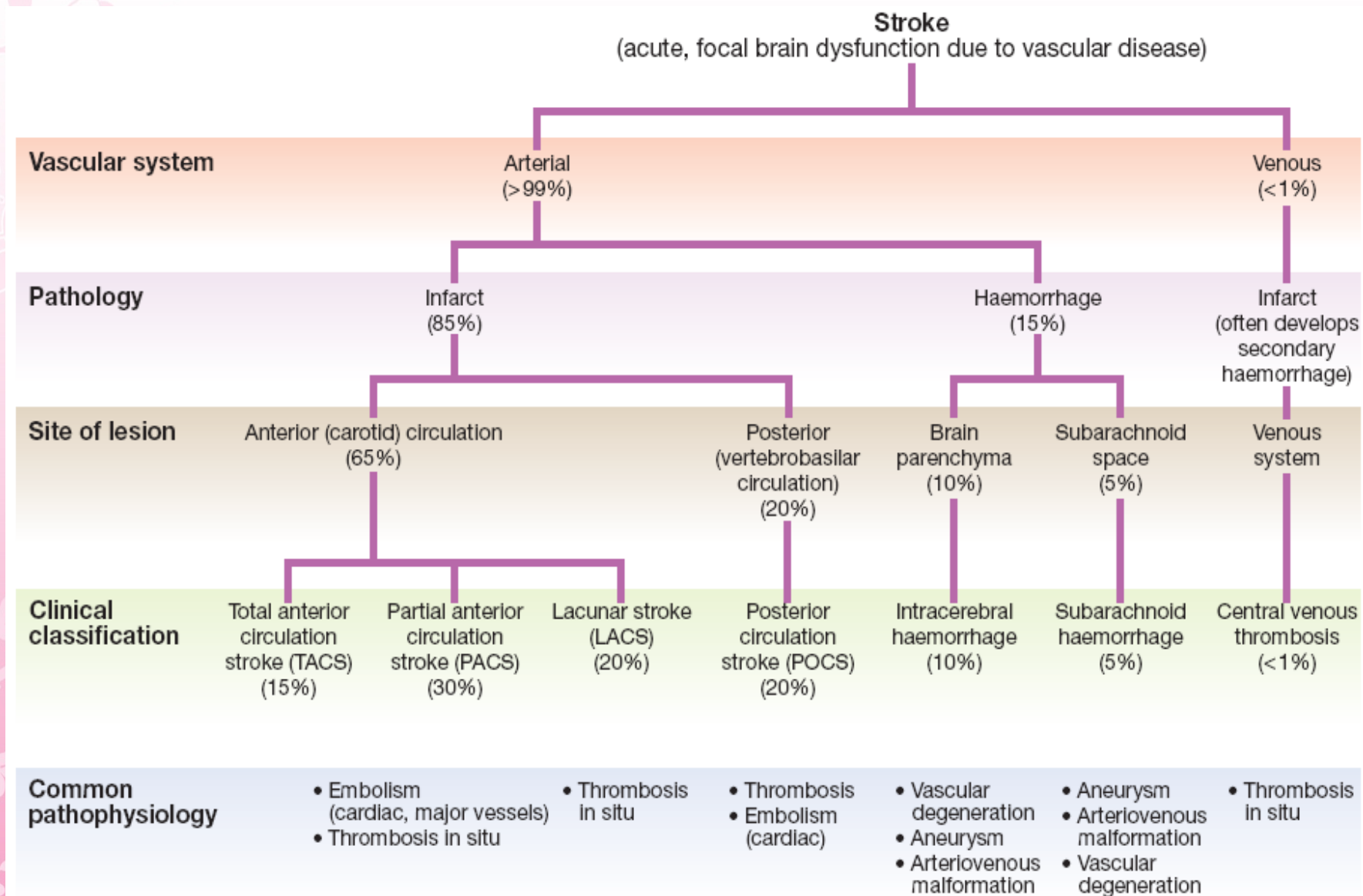
25.11.2014



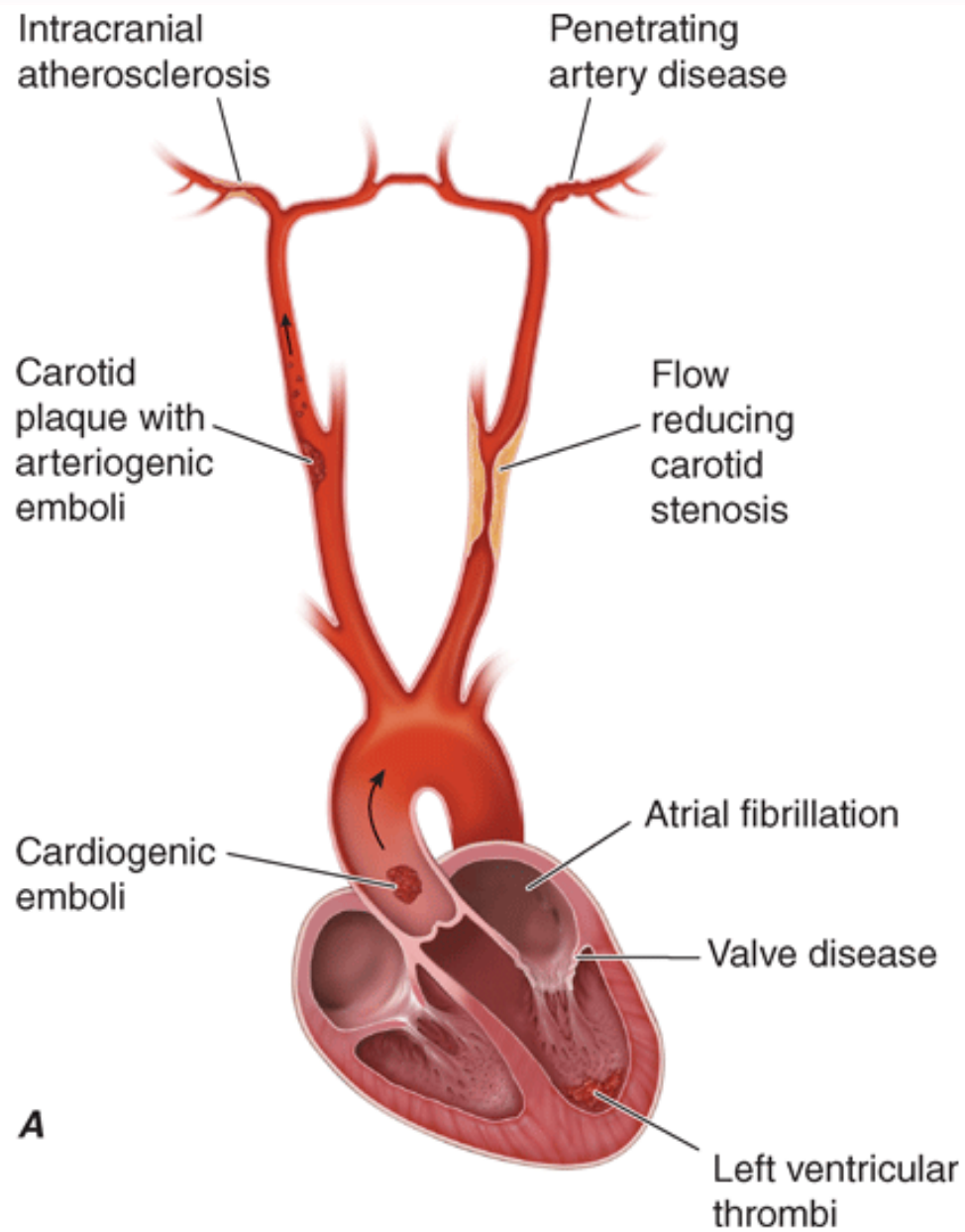
# *Cerebrovascular Disease*

- Cerebrovascular disease is the third most common cause of death in high-income countries after cancers and ischaemic heart disease, and the most common cause of severe physical disability

- 
- Stroke is the most common clinical manifestation of cerebrovascular disease, and results in episodes of brain dysfunction due to focal ischaemia or haemorrhage



**Fig. 27.1** A classification of stroke disease.



# 1

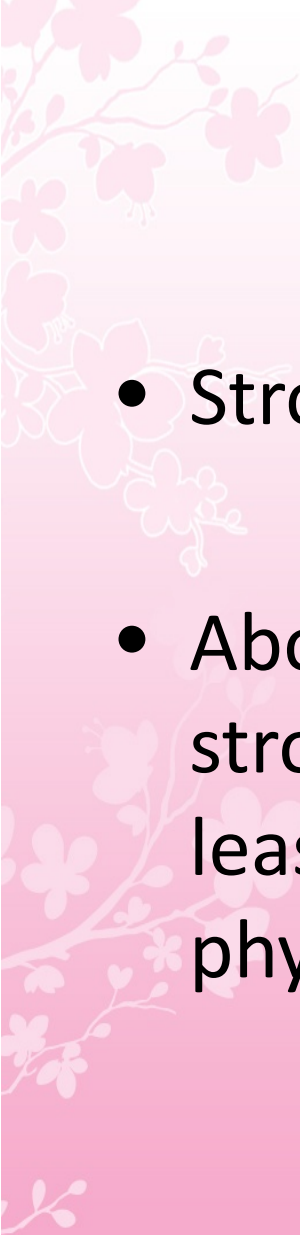
## 27.1 Risk factors for stroke


### Fixed risk factors

- Age
- Gender (male > female except at extremes of age)
- Race (Afro-Caribbean > Asian > European)
- Previous vascular event
  - Myocardial infarction
  - Stroke
  - Peripheral vascular disease
- Heredity
- High fibrinogen

### Modifiable risk factors

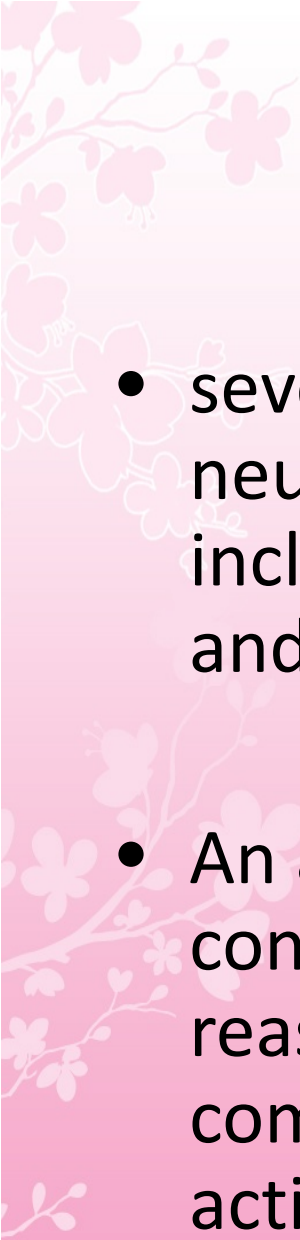
- |   |  |
|---|--|
| <ul style="list-style-type: none"><li>• Blood pressure</li><li>• Cigarette smoking</li><li>• Hyperlipidaemia</li><li>• Heart disease<ul style="list-style-type: none"><li>Atrial fibrillation</li><li>Congestive cardiac failure</li><li>Infective endocarditis</li></ul></li></ul> | <ul style="list-style-type: none"><li>• Diabetes mellitus</li><li>• Excessive alcohol intake</li><li>• Oestrogen-containing drugs<ul style="list-style-type: none"><li>Oral contraceptive pill</li><li>Hormone replacement therapy</li></ul></li><li>• Polycythaemia</li></ul> |
|---|--|

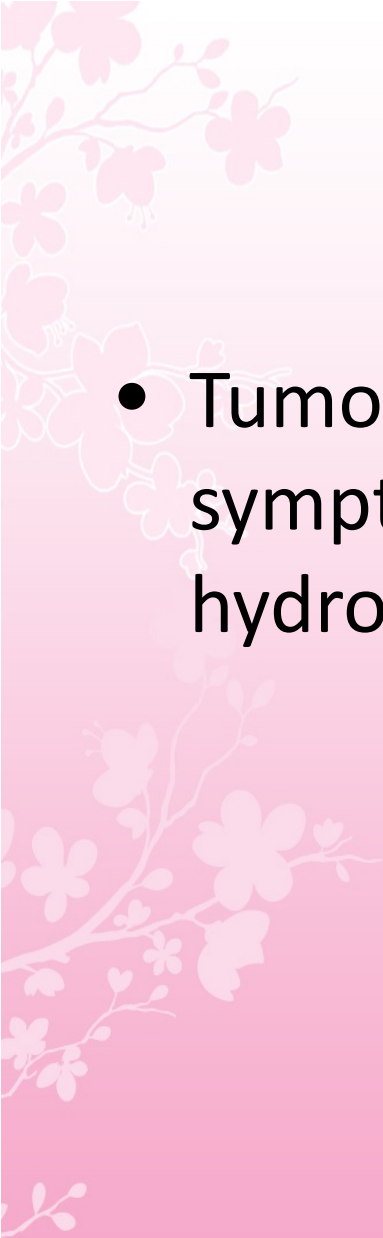
- 
- Stroke is a common medical emergency
  - About one-fifth of patients with an acute stroke die within a month of the event and at least half of those who survive are left with physical disability

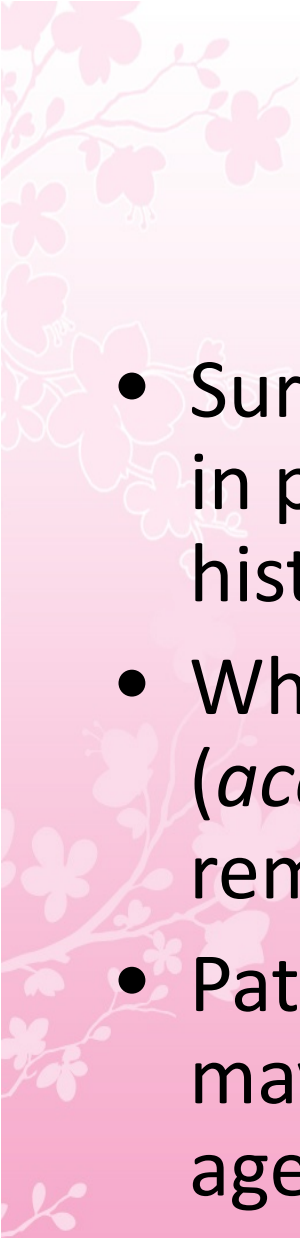



# Approach to the Patient: Cerebrovascular Disease

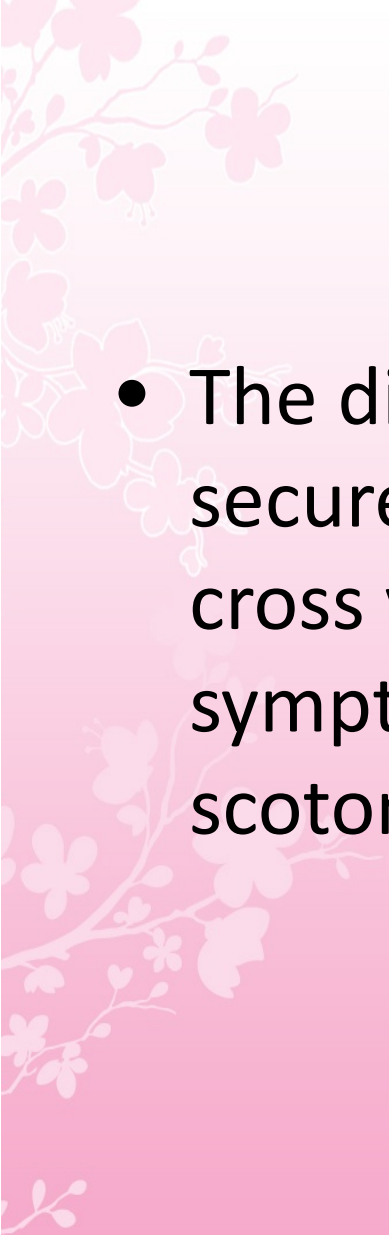


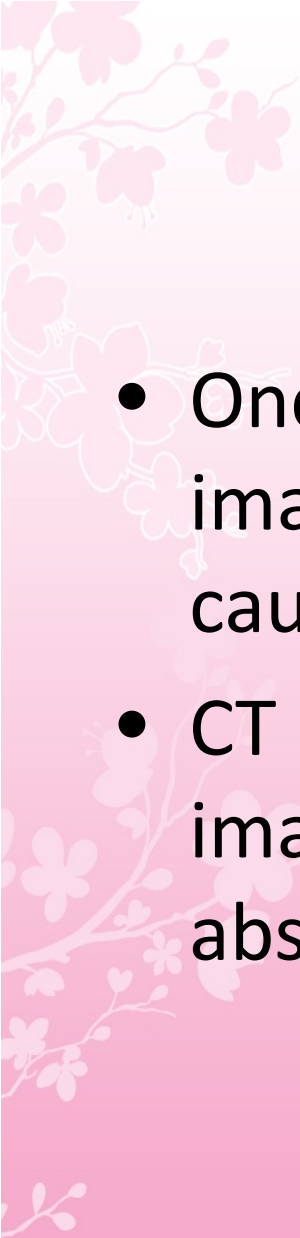
- 
- several common causes of sudden-onset neurologic symptoms that may mimic stroke, including seizure, intracranial tumor, migraine, and metabolic encephalopathy
  - An adequate history from an observer that no convulsive activity occurred at the onset reasonably excludes seizure; however, ongoing complex partial seizures without tonic-clonic activity may mimic stroke

- 
- Tumors may present with acute neurologic symptoms due to hemorrhage, seizure, or hydrocephalus

- 
- Surprisingly, migraine can mimic stroke, even in patients without a significant migraine history
  - When it develops without head pain (*acephalgic migraine*), the diagnosis may remain elusive
  - Patients without any prior history of migraine may develop acephalgic migraine even after age 65

- 
- A sensory disturbance is often prominent, and the sensory deficit, as well as any motor deficits, tends to migrate slowly across a limb over minutes rather than seconds as with stroke

- 
- The diagnosis of migraine becomes more secure as the cortical disturbance begins to cross vascular boundaries or if typical visual symptoms are present such as scintillating scotomata

- 
- Once the diagnosis of stroke is made, a brain imaging study is necessary to determine if the cause of stroke is ischemia or hemorrhage
  - CT imaging of the brain is the standard imaging modality to detect the presence or absence of intracranial hemorrhage



## 27.3 Differential diagnosis of stroke and TIA

### 'Structural' stroke mimics

- Primary cerebral tumours
- Metastatic cerebral tumours
- Subdural haematoma
- Cerebral abscess
- Peripheral nerve lesions (vascular or compressive)
- Demyelination

### 'Functional' stroke mimics

- Todd's paresis (after epileptic seizure)
- Hypoglycaemia
- Migrainous aura (with or without headache)
- Focal seizures
- Ménière's disease or other vestibular disorder
- Conversion disorder (p. 246)
- Encephalitis

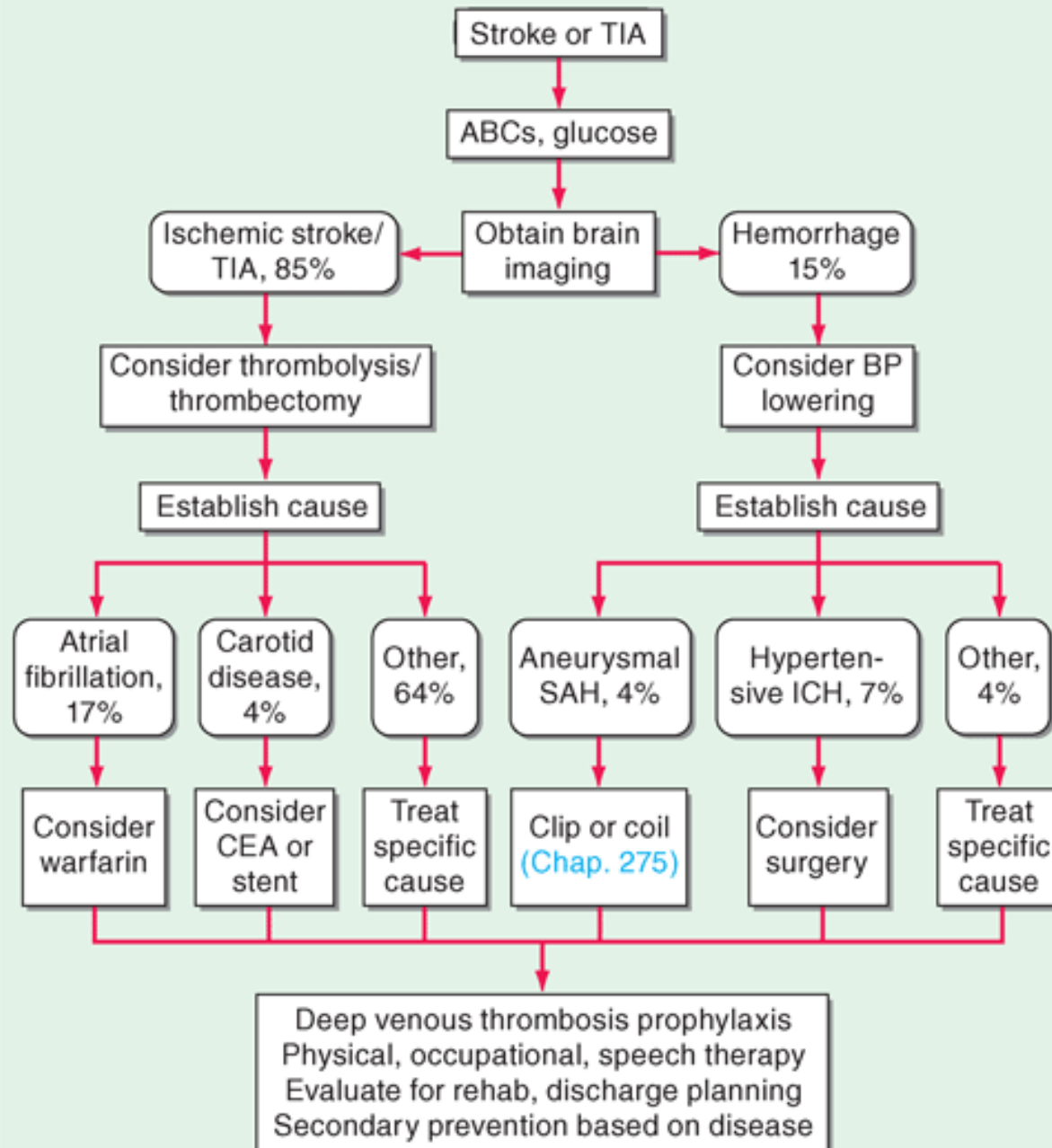


## 27.4 Characteristic features of stroke and non-stroke syndromes ('stroke mimics')

| Feature                      | Stroke                           | Stroke mimics  |
|------------------------------|----------------------------------|--|
| <b>Symptom onset</b>         | Sudden (minutes)                 | Often slower onset   |
| <b>Symptom progression</b>   | Rapidly reaches maximum severity | Often gradual onset  |
| <b>Severity of deficit</b>   | Unequivocal                      | May be variable/uncertain  |
| <b>Pattern of deficit</b>    | Hemispheric pattern              | May be non-specific with confusion, memory loss, balance disturbance |
| <b>Loss of consciousness</b> | Uncommon                         | More common  |

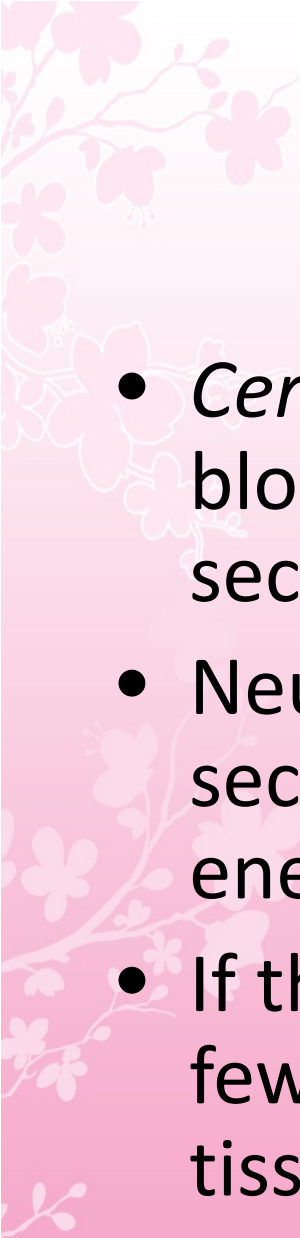


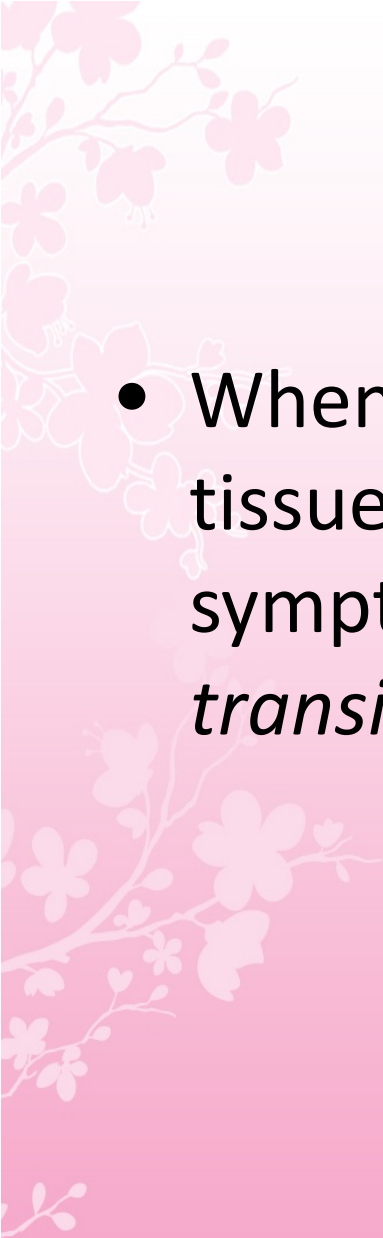
## ALGORITHM FOR STROKE AND TIA MANAGEMENT

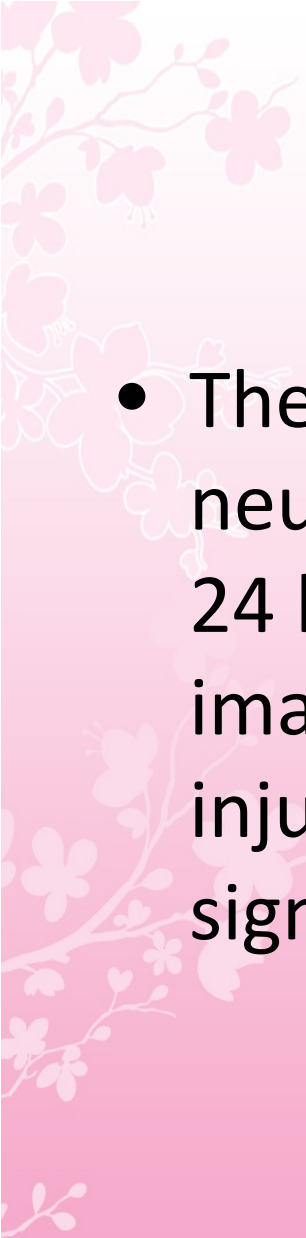


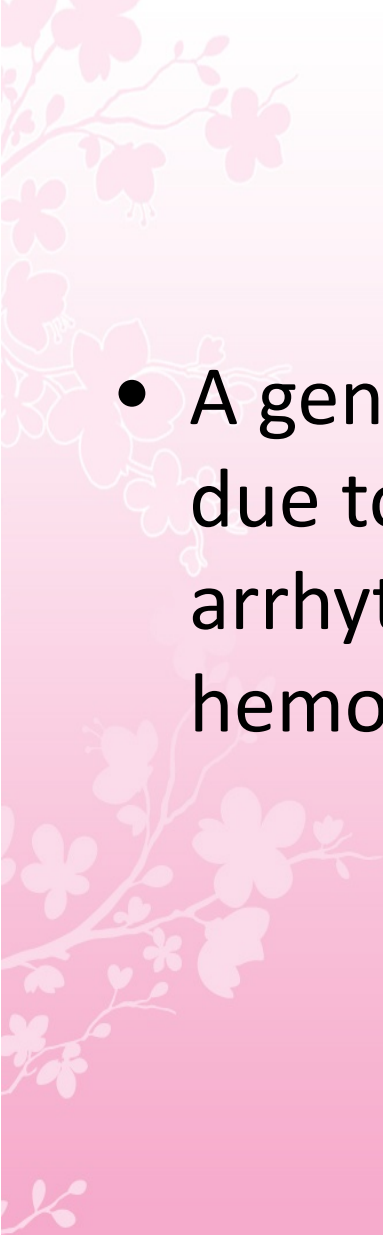
A decorative floral pattern in the top-left corner of the slide, featuring pink and white blossoms on thin branches.

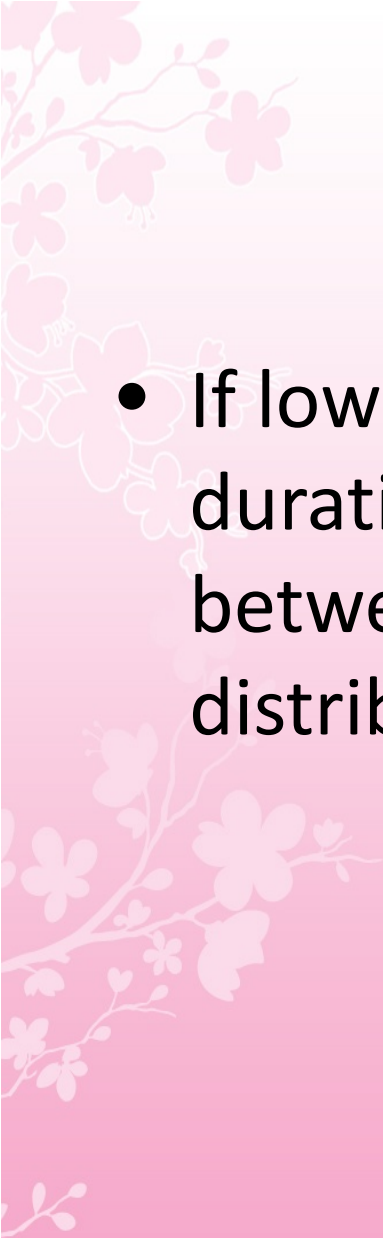
# Cerebral Ischaemia


- 
- *Cerebral ischemia* is caused by a reduction in blood flow that lasts longer than several seconds
  - Neurologic symptoms are manifest within seconds because neurons lack glycogen, so energy failure is rapid
  - If the cessation of flow lasts for more than a few minutes, *infarction* or death of brain tissue results

- 
- When blood flow is quickly restored, brain tissue can recover fully and the patient's symptoms are only transient: This is called a *transient ischemic attack (TIA)*


- 
- The standard definition of TIA requires that all neurologic signs and symptoms resolve within 24 hours regardless of whether there is imaging evidence of new permanent brain injury; stroke has occurred if the neurologic signs and symptoms last for >24 hours

- 
- A generalized reduction in cerebral blood flow due to systemic hypotension (e.g., cardiac arrhythmia, myocardial infarction, or hemorrhagic shock) usually produces syncope

- 
- If low cerebral blood flow persists for a longer duration, then infarction in the border zones between the major cerebral artery distributions may develop (Watershed Infarct)

- 
- In more severe instances, *global hypoxia-ischemia* causes widespread brain injury; the constellation of cognitive sequelae that ensues is called *hypoxic-ischemic encephalopathy*




- 
- *Focal ischemia* or infarction, conversely, is usually caused by thrombosis of the cerebral vessels themselves or by emboli from a proximal arterial source or the heart.

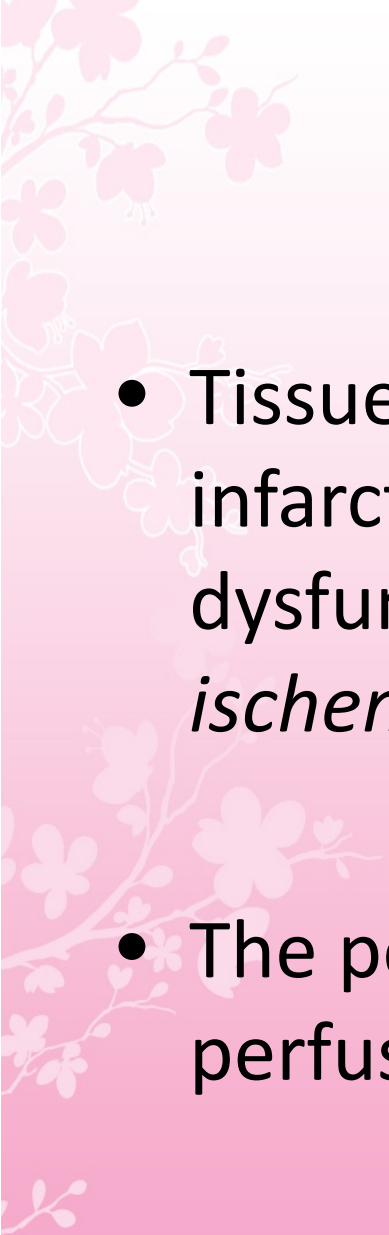
A decorative floral pattern in the top-left corner of the slide, featuring pink and white blossoms on thin branches.

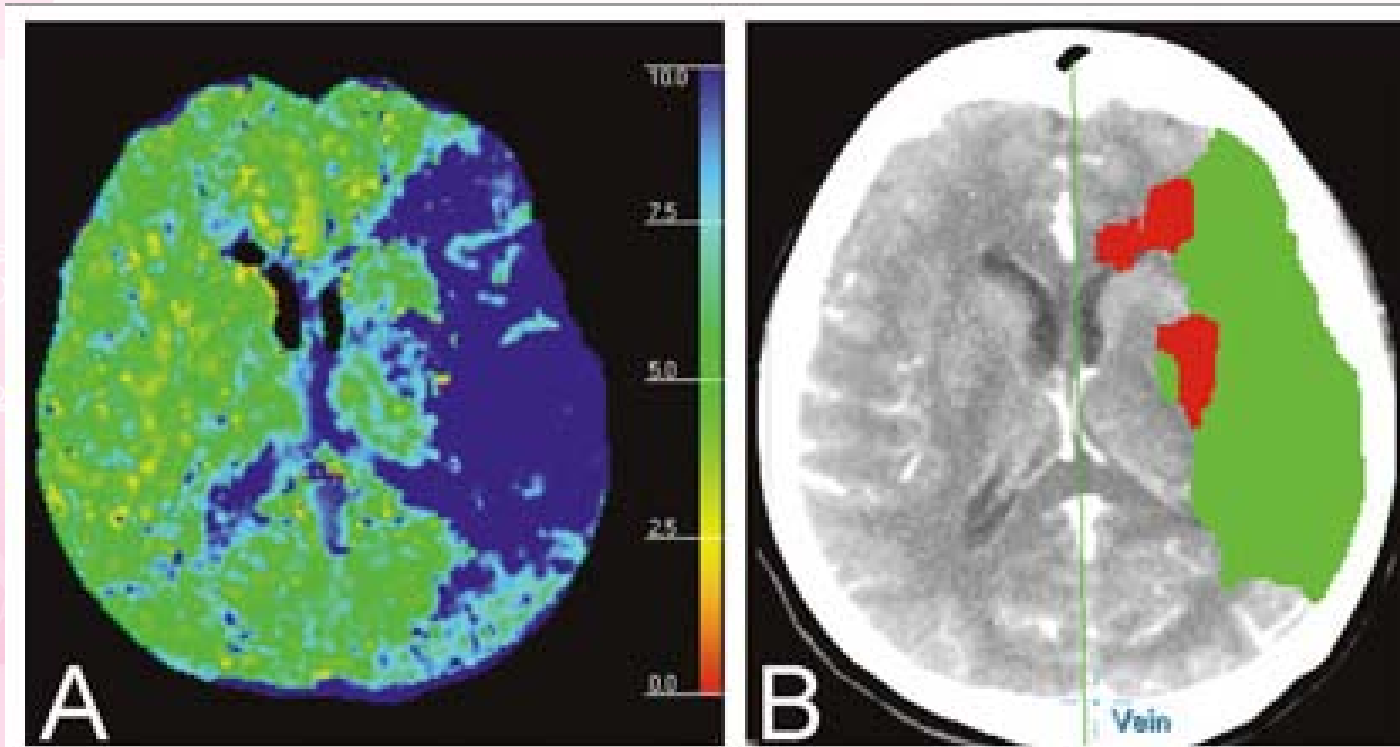
# Pathophysiology of Ischemic Stroke

# Pathophysiology of Ischemic Stroke

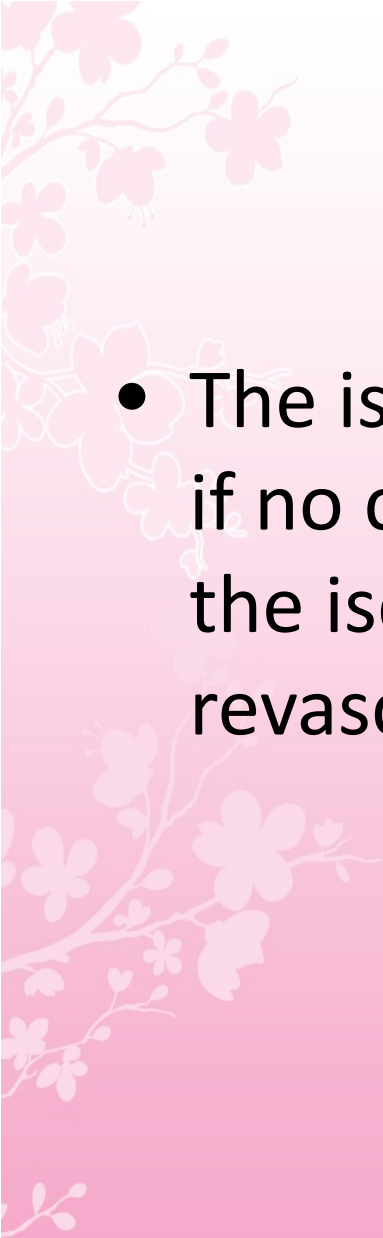
- Acute occlusion of an intracranial vessel causes reduction in blood flow to the brain region it supplies
- The magnitude of flow reduction is a function of collateral blood flow and this depends on individual vascular anatomy, the site of occlusion, and likely systemic blood pressure

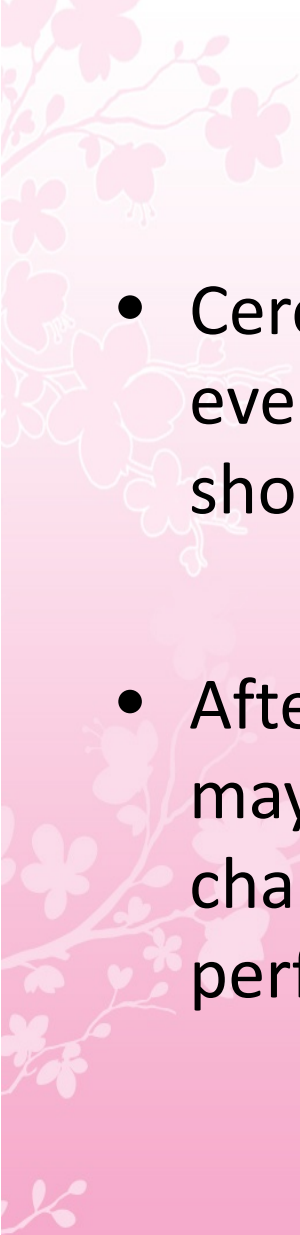
- 
- A decrease in cerebral blood flow to zero causes death of brain tissue within 4–10 minutes;
  - values  $<16\text{--}18$  mL/100 g tissue per minute cause infarction within an hour; and
  - values  $<20$  mL/100 g tissue per minute cause ischemia without infarction unless prolonged for several hours or days

- 
- Tissue surrounding the core region of infarction is ischemic but reversibly dysfunctional and is referred to as the *ischemic penumbra*
  - The penumbra may be imaged by using perfusion-diffusion imaging with MRI or CT

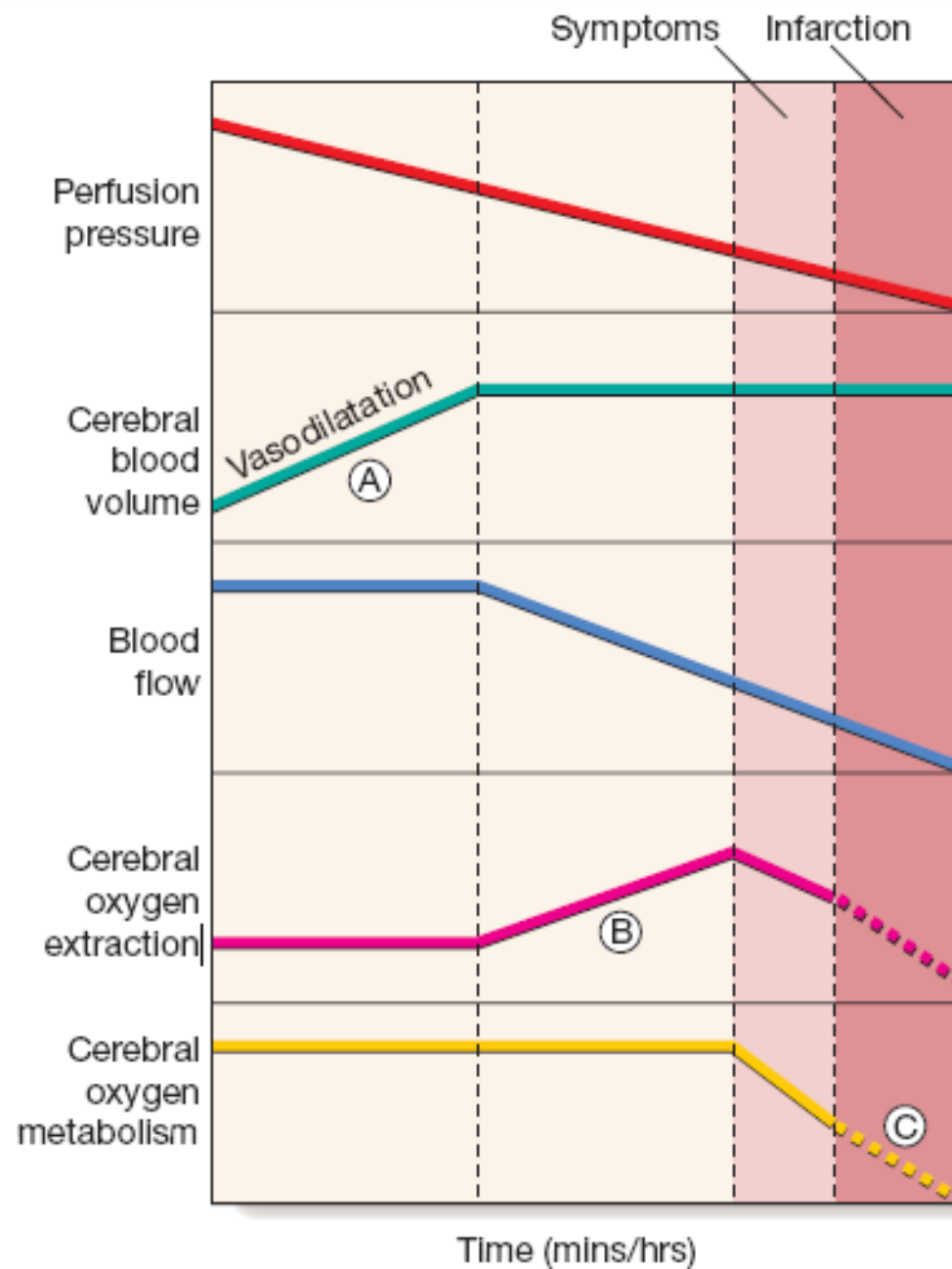


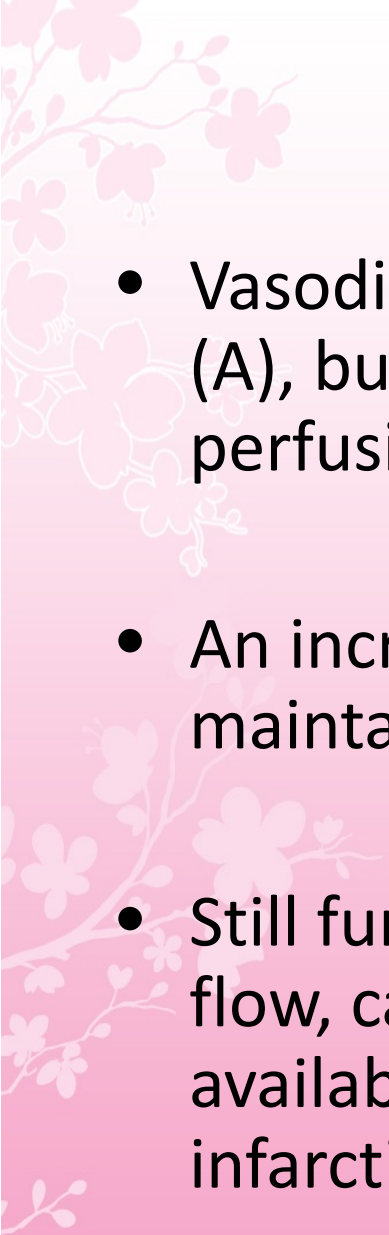
**A.**CT perfusion mean-transit time map showing delayed perfusion of the left MCA distribution (blue).  
**B.**Predicted region of infarct (*red?*) and penumbra (*green*) based on CT perfusion data

- 
- The ischemic penumbra will eventually infarct if no change in flow occurs, and hence saving the ischemic penumbra is the goal of revascularization therapies

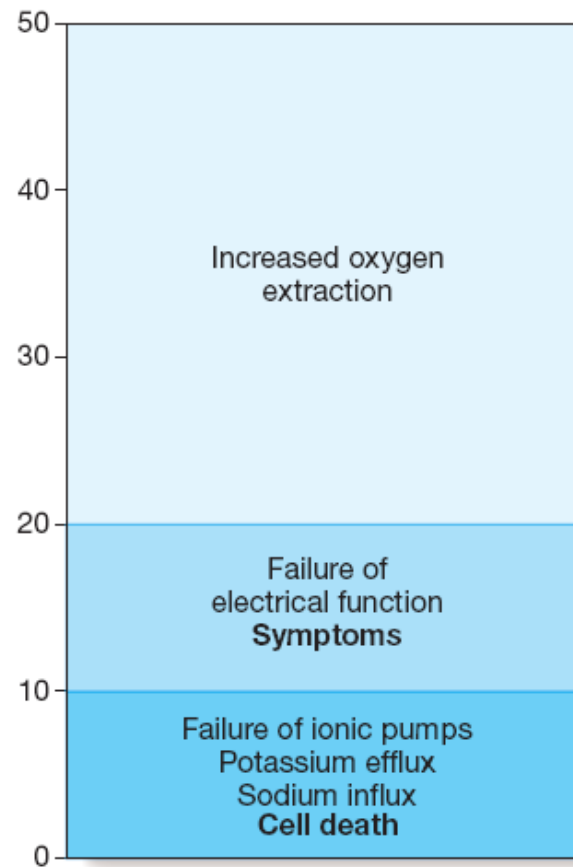
- 
- Cerebral infarction takes some hours to complete, even though the patient's deficit may be maximal shortly after the vascular occlusion
  - After the occlusion of a cerebral artery, infarction may be forestalled by the opening of anastomotic channels from other arterial territories that restore perfusion to its territory








- 
- Vasodilatation initially maintains cerebral blood flow (A), but after maximal vasodilatation further falls in perfusion pressure lead to a decline in blood flow
  - An increase in tissue oxygen extraction, however, maintains the cerebral metabolic rate for oxygen (B)
  - Still further falls in perfusion, and therefore blood flow, cannot be compensated; cerebral oxygen availability falls and symptoms appear, then infarction (C)


Cerebral blood flow  
mL/100 g/min



- 
- Symptoms of cerebral ischaemia appear when the blood flow has fallen to less than half of normal and energy supply is insufficient to sustain neuronal electrical function
  - Full recovery can occur if this level of flow is returned to normal but not if it is sustained

- 
- Further blood flow reduction below the next threshold causes failure of cell ionic pumps and starts the ischaemic cascade, leading to cell death

- 
- As the cerebral blood flow declines, different neuronal functions fail at various thresholds
  - Once blood flow falls below the threshold for the maintenance of electrical activity, neurological deficit develops

- 
- At this level of blood flow, the neurons are still viable; if the blood flow increases again, function returns and the patient will have had a transient ischaemic attack (TIA)
  - However, if the blood flow falls further, a level is reached at which irreversible cell death starts

Hypoxia

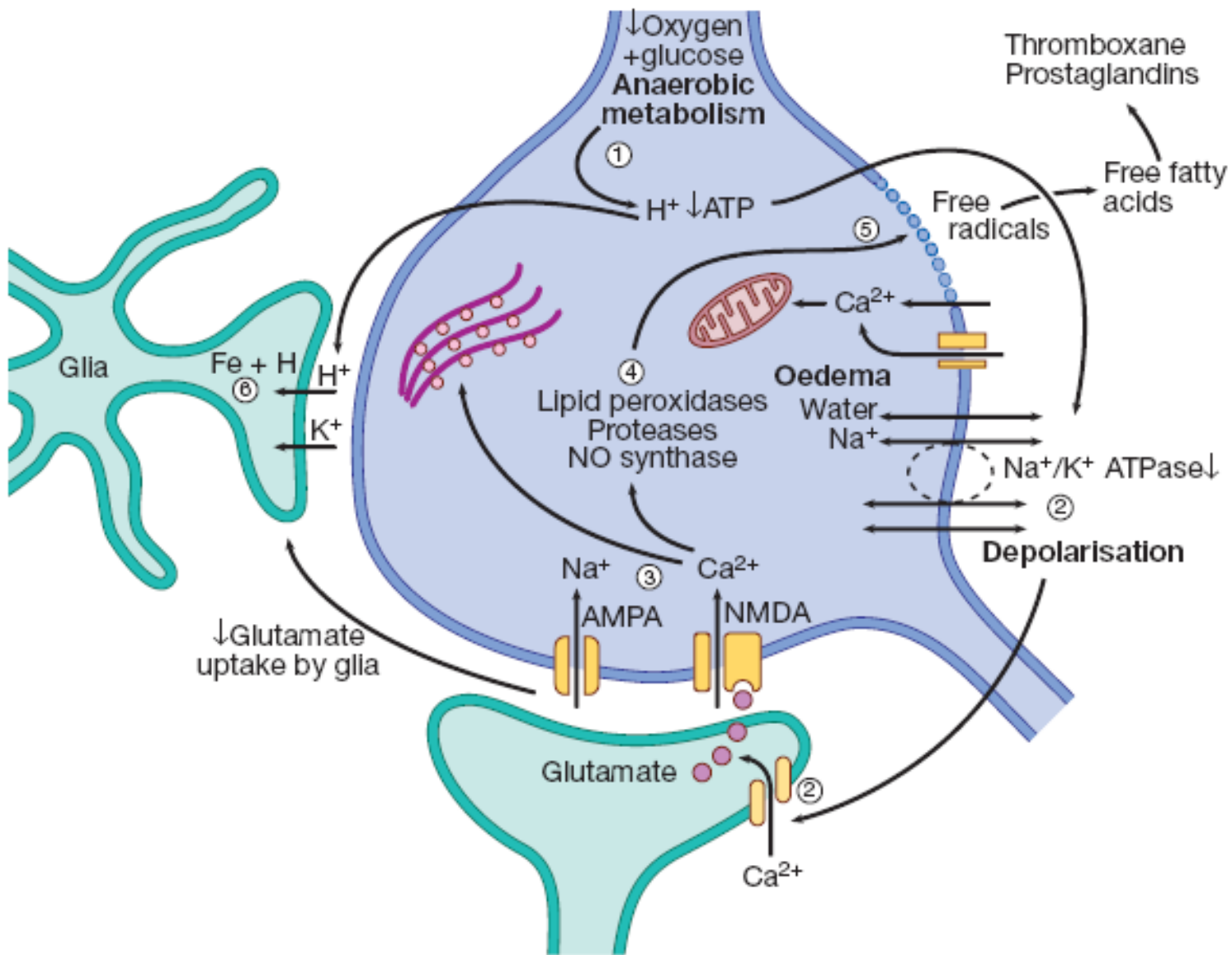


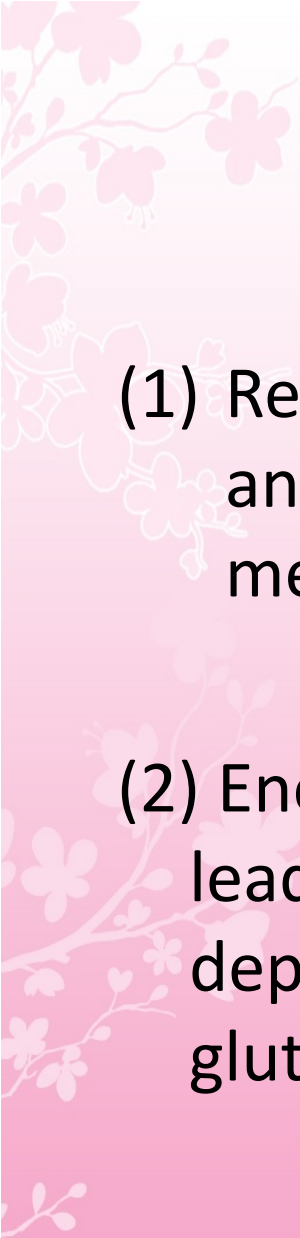
inadequate supply of adenosine triphosphate (ATP),  
which leads to failure of membrane pumps



allowing influx of sodium and water into the cell  
(cytotoxic oedema) and the release of the excitatory  
neurotransmitter glutamate into the extracellular  
fluid








(1) Reduction of blood flow reduces supply of oxygen and hence ATP.  $H^+$  is produced by anaerobic metabolism of available glucose


(2) Energy-dependent membrane ionic pumps fail, leading to cytotoxic oedema and membrane depolarisation, allowing calcium entry and releasing glutamate



(3) Calcium enters cells via glutamate-gated channels and

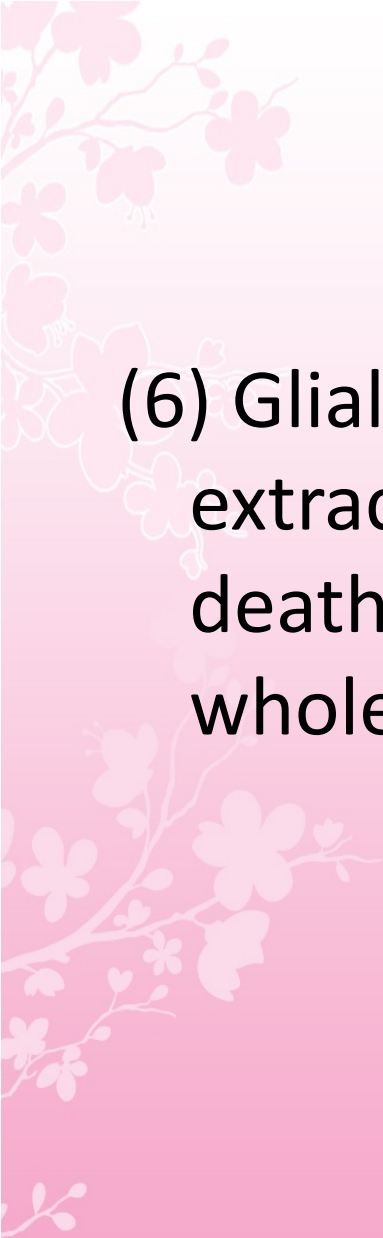


(4) activates destructive intracellular enzymes

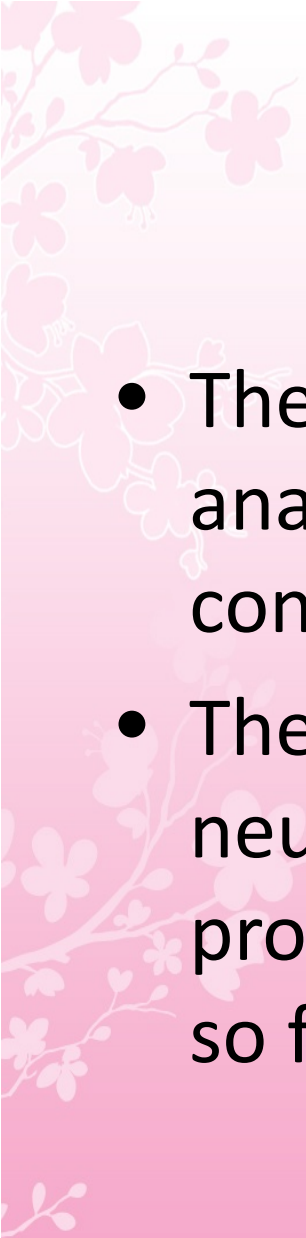


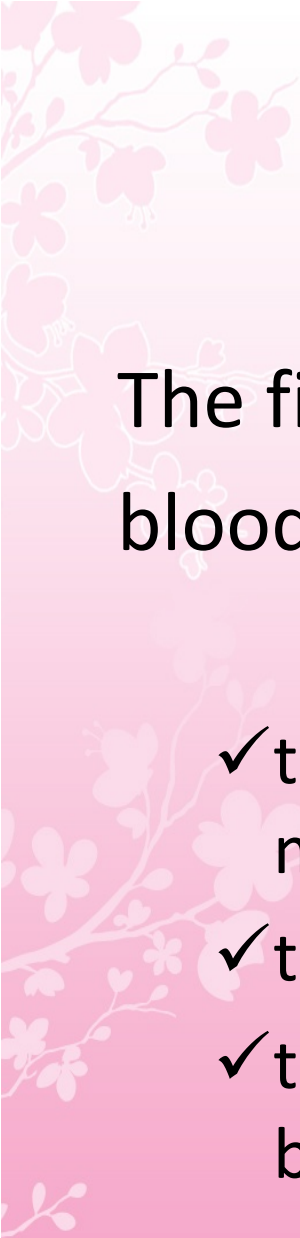
(5) destroying intracellular organelles and cell membrane, with release of free radicals.

Free fatty acid release activates pro-coagulant pathways that exacerbate local ischaemia.



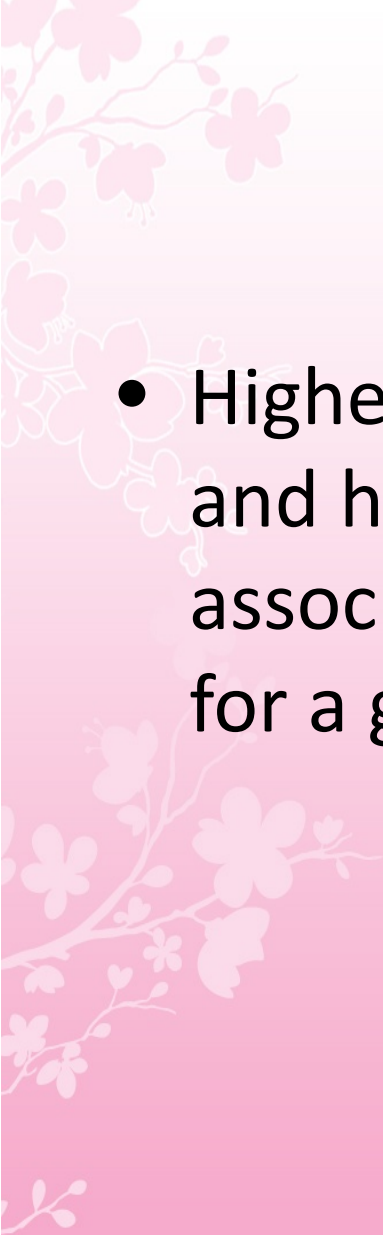
(6) Glial cells take up  $H^+$ , can no longer take up extracellular glutamate and also suffer cell death, leading to liquefactive necrosis of whole arterial territory

- 
- The infarction process is worsened by the anaerobic production of lactic acid and consequent fall in tissue pH
  - There have been attempts to develop neuroprotective drugs to slow down the processes leading to irreversible cell death but so far these have proved disappointing

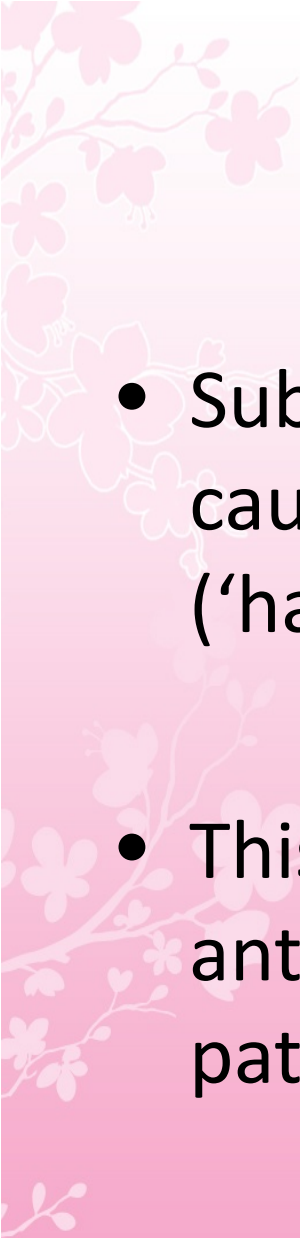


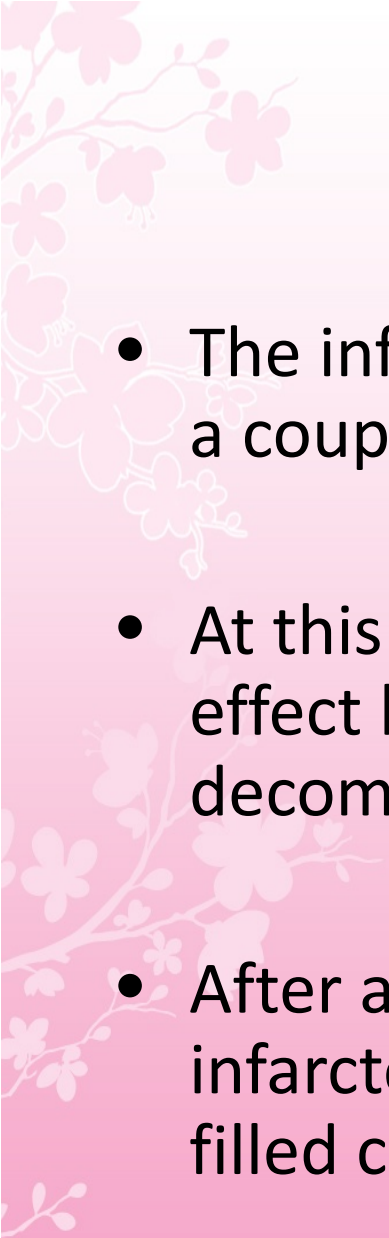
The final outcome of the occlusion of a cerebral blood vessel therefore depends upon

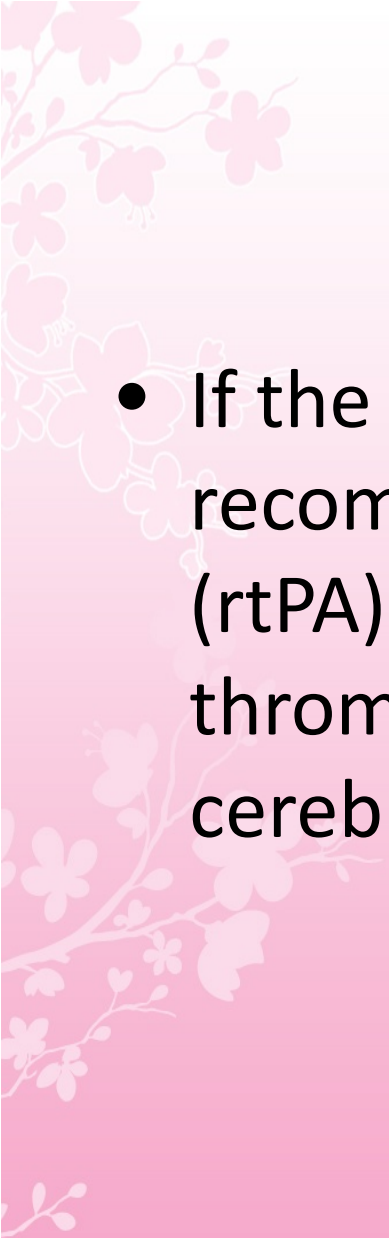
- ✓ the competence of the circulatory homeostatic mechanisms,
- ✓ the metabolic demand, and
- ✓ the severity and duration of the reduction in blood flow

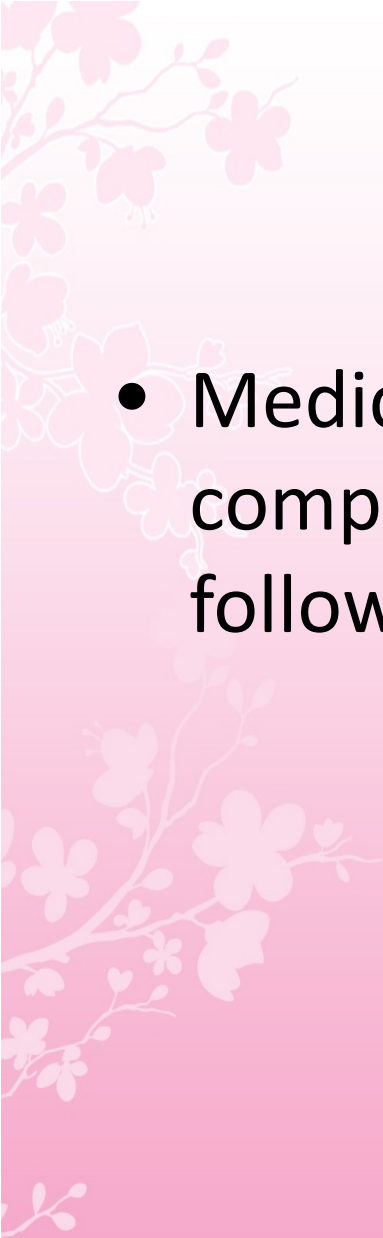
- 
- Higher brain temperature, as occurs in fever, and higher blood sugar have both been associated with a greater volume of infarction for a given reduction in cerebral blood flow

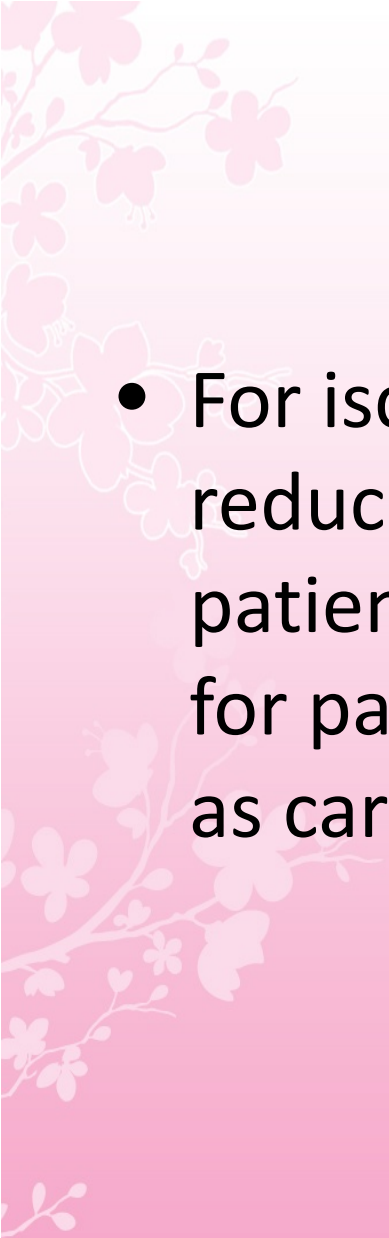


- 
- Subsequent restoration of blood flow may cause haemorrhage into the infarcted area ('haemorrhagic transformation')
  - This is particularly likely in patients given antithrombotic or thrombolytic drugs, and in patients with larger infarcts

- 
- The infarct swells with time and is at its maximal size a couple of days after stroke onset
  - At this stage, it may be big enough to exert mass effect both clinically and radiologically; sometimes, decompressive craniectomy is required
  - After a few weeks, the oedema subsides and the infarcted area is replaced by a sharply defined fluid-filled cavity

- 
- If the stroke is ischemic, administration of recombinant tissue plasminogen activator (rtPA) or endovascular mechanical thrombectomy may be beneficial in restoring cerebral perfusion

- 
- Medical management to reduce the risk of complications becomes the next priority, followed by plans for secondary prevention.


- 
- For ischemic stroke, several strategies can reduce the risk of subsequent stroke in all patients, while other strategies are effective for patients with specific causes of stroke such as cardiac embolus and carotid atherosclerosis

A decorative floral pattern in the top-left corner, featuring pink and white blossoms on thin branches, set against a light pink background.

# Small-Vessel Stroke

## Small-Vessel Stroke

- *lacunar infarction* refers to infarction following atherothrombotic or lipohyalinotic occlusion of a small artery (30–300  $\mu$ m) in the brain
- The term *small-vessel stroke* denotes occlusion of such a small penetrating artery and is now the preferred term

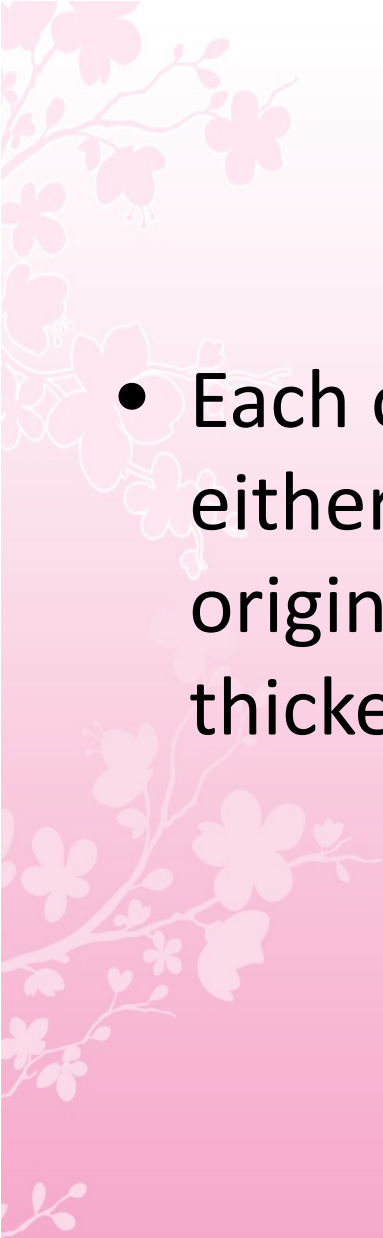
- 
- Small-vessel strokes account for 20% of all strokes
  - These infarcts range in size from 3 mm to 2 cm in diameter
  - Hypertension and age are the principal risk factors




MCA stem,  
the arteries comprising the circle of Willis and  
the basilar and vertebral arteries all



give rise to 30- to 300- $\mu$ m branches that penetrate  
the deep gray and white matter of the  
cerebrum or brainstem

- 
- Each of these small branches can occlude either by atherothrombotic disease at its origin or by the development of lipohyalinotic thickening

- 
- Thrombosis of these vessels causes small infarcts that are referred to as *lacunes* (Latin for "lake" of fluid noted at autopsy)

# Clinical Manifestation

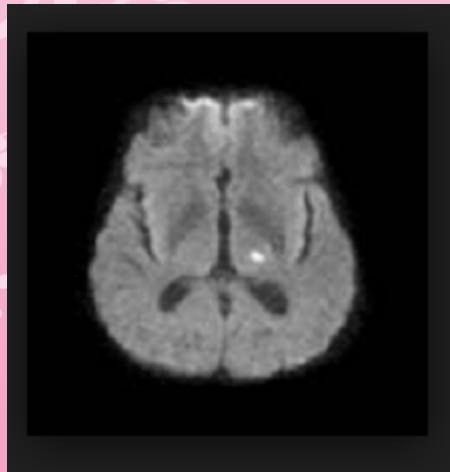
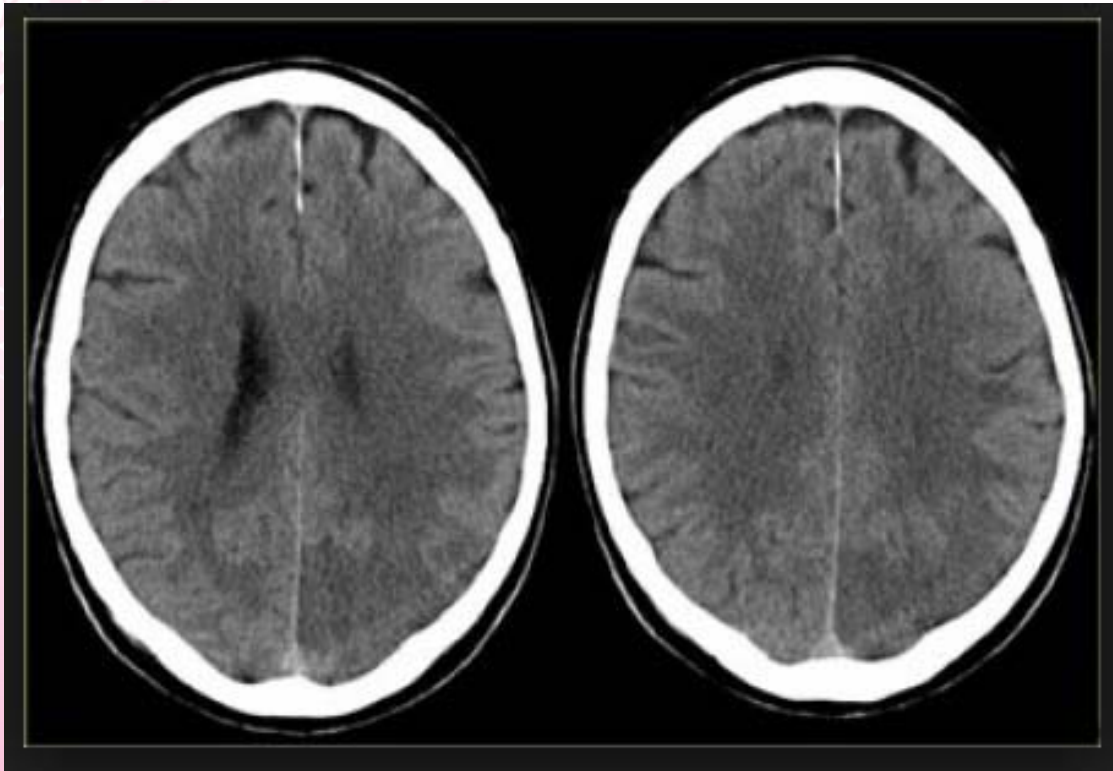
- most common *lacunar syndromes* are the following:
  - (1) *Pure motor hemiparesis* from an infarct in the posterior limb of the internal capsule or basis pontis; the face, arm, and leg are almost always involved



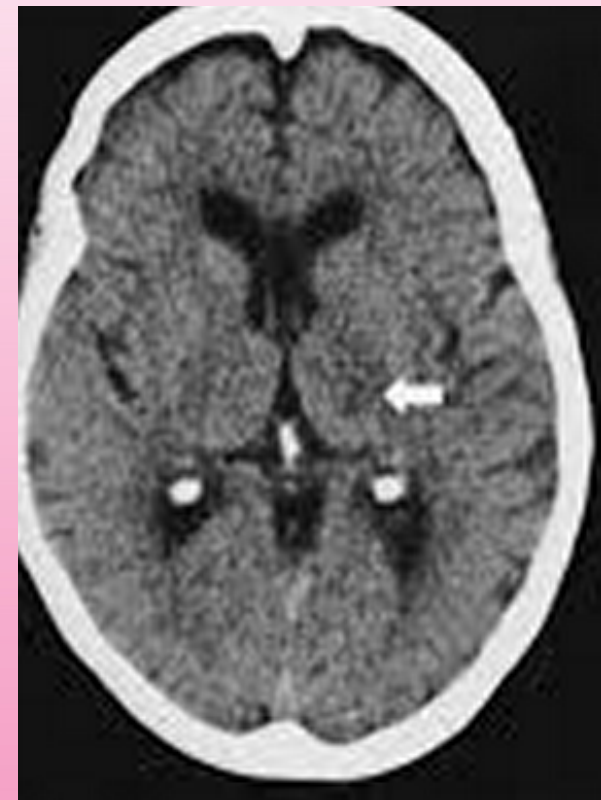
(2) *Pure sensory stroke* from an infarct in the ventral thalamus

(3) *ataxic hemiparesis* from an infarct in the ventral pons or internal capsule

(4) *dysarthria and a clumsy hand or arm* due to infarction in the ventral pons or in the genu of the internal capsule




Left thalamic  
lacunar infarct




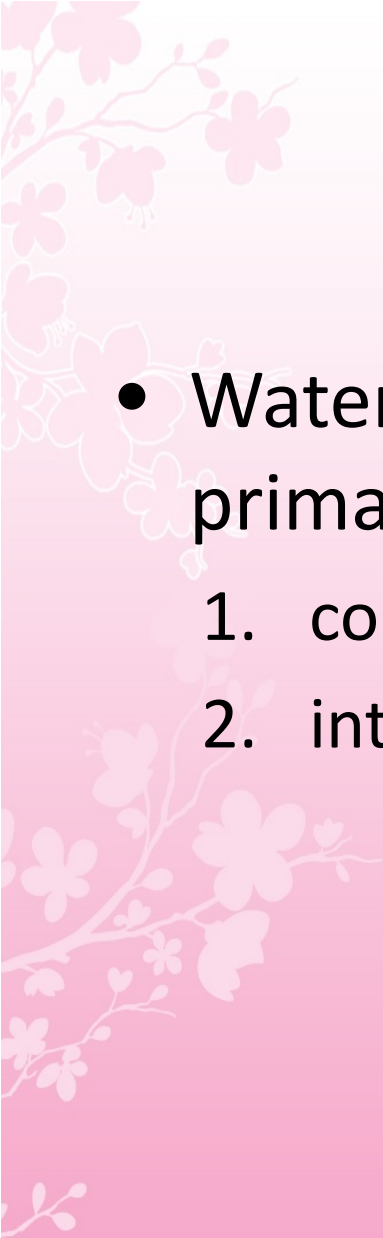


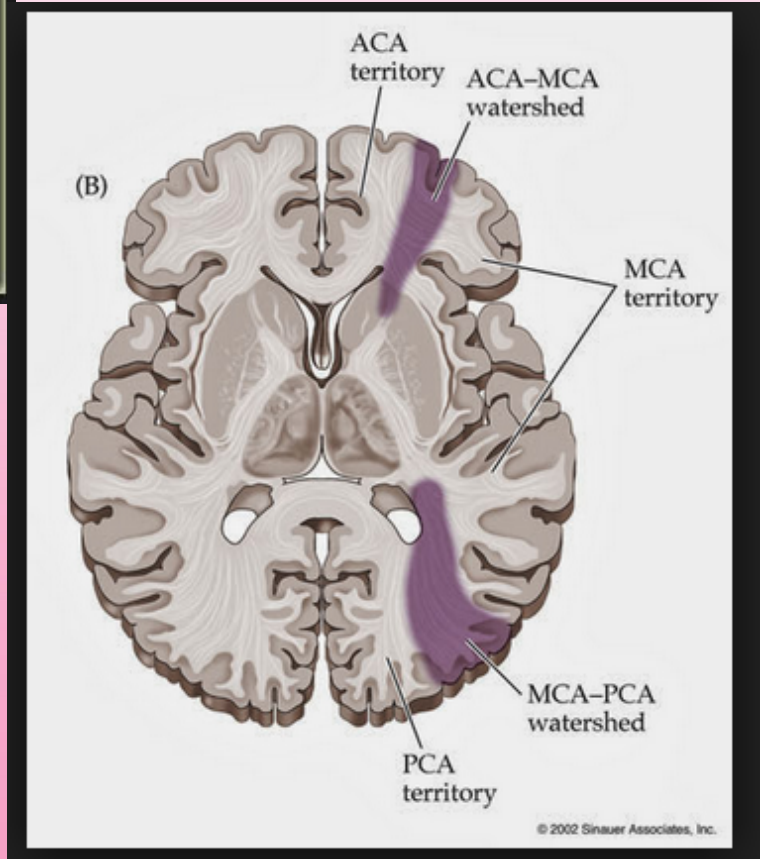
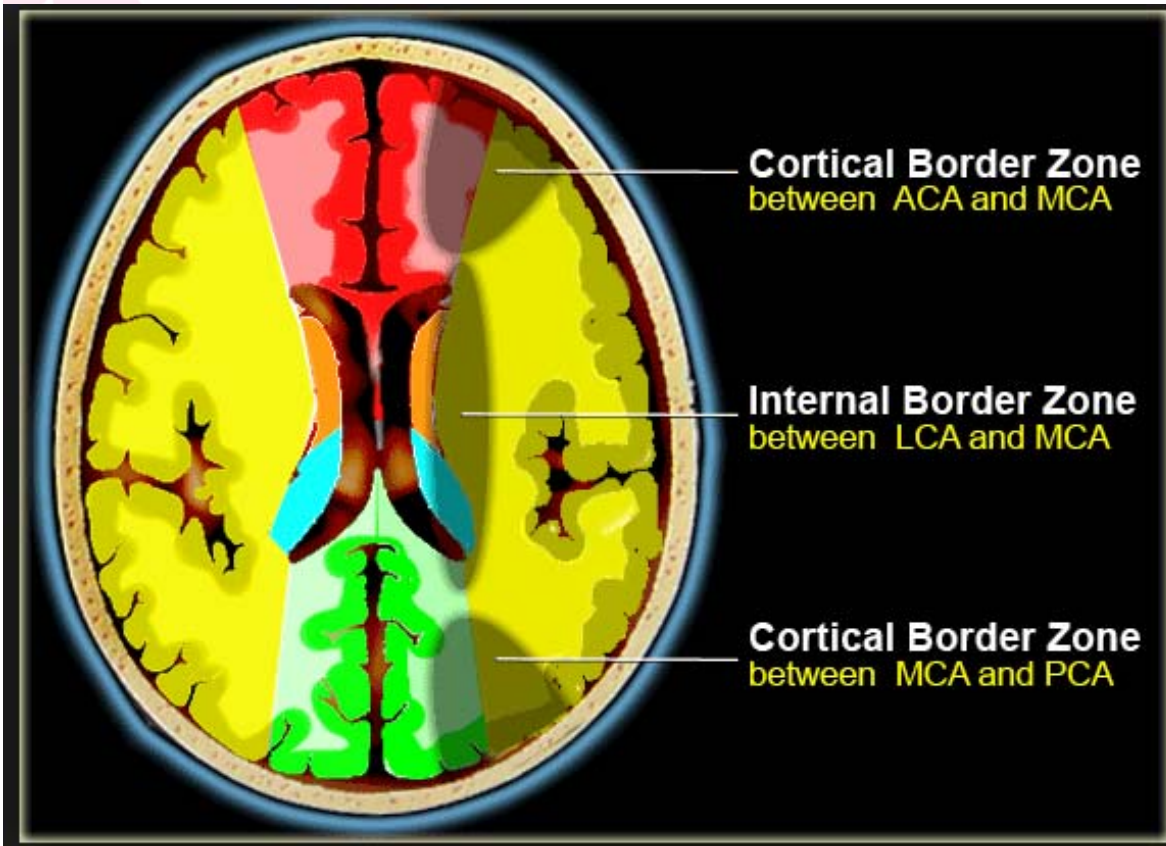
# Watershed Infarct

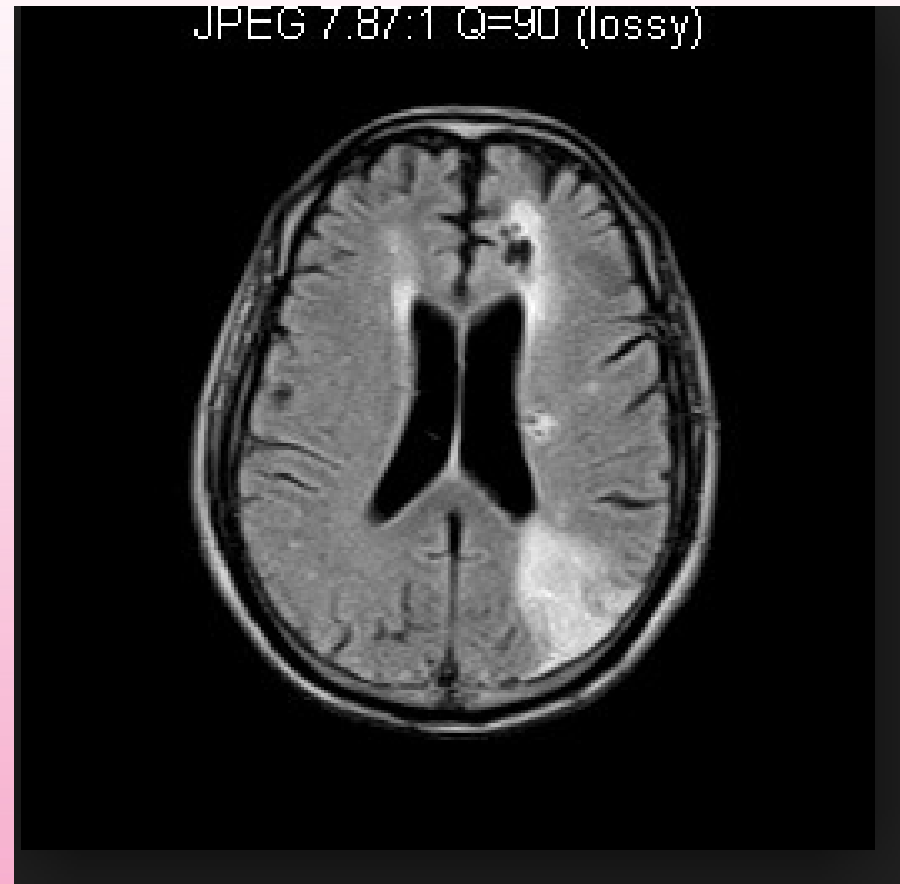
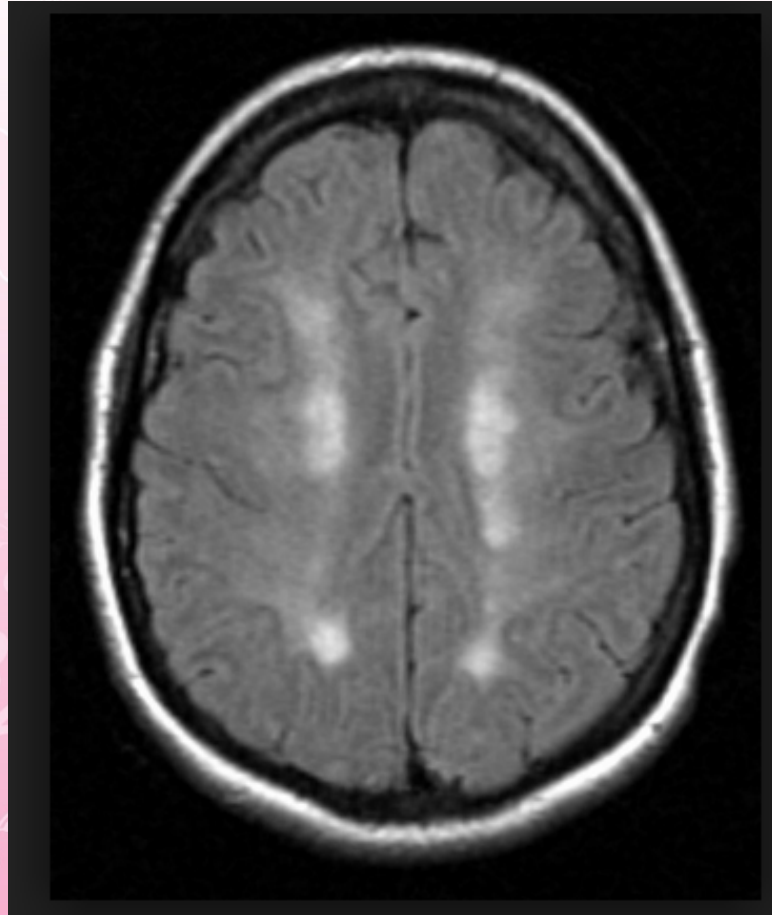
- 
- A watershed stroke or watershed infarct is defined as an ischaemia, or blood flow blockage, that is localized to the border zones between the territories of two major arteries in the brain

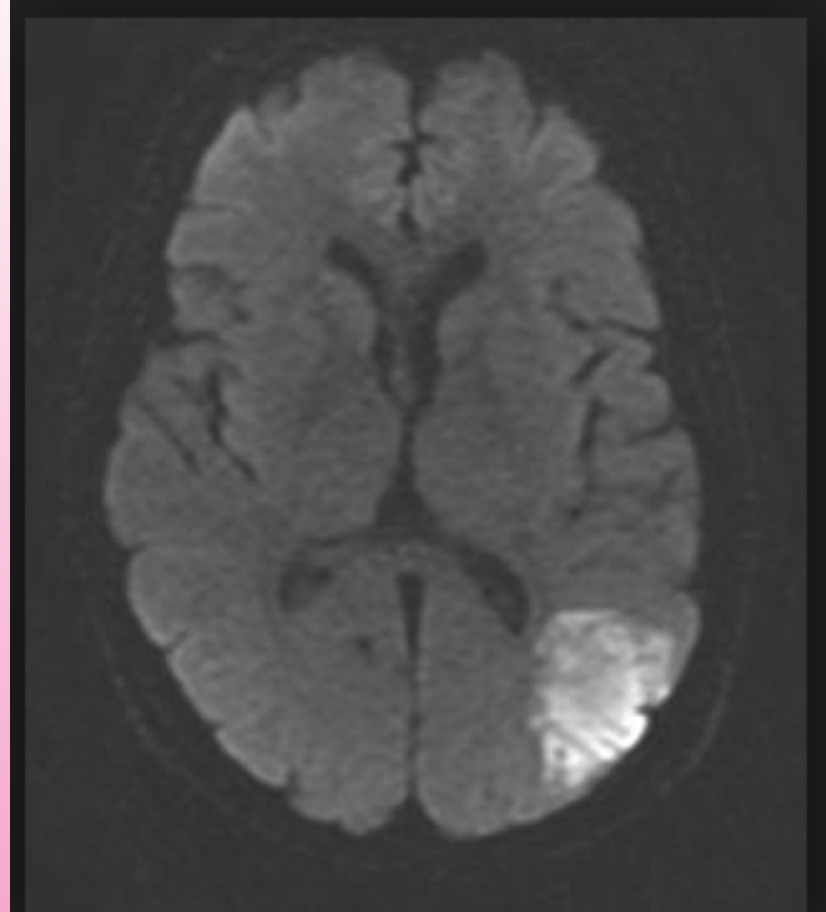
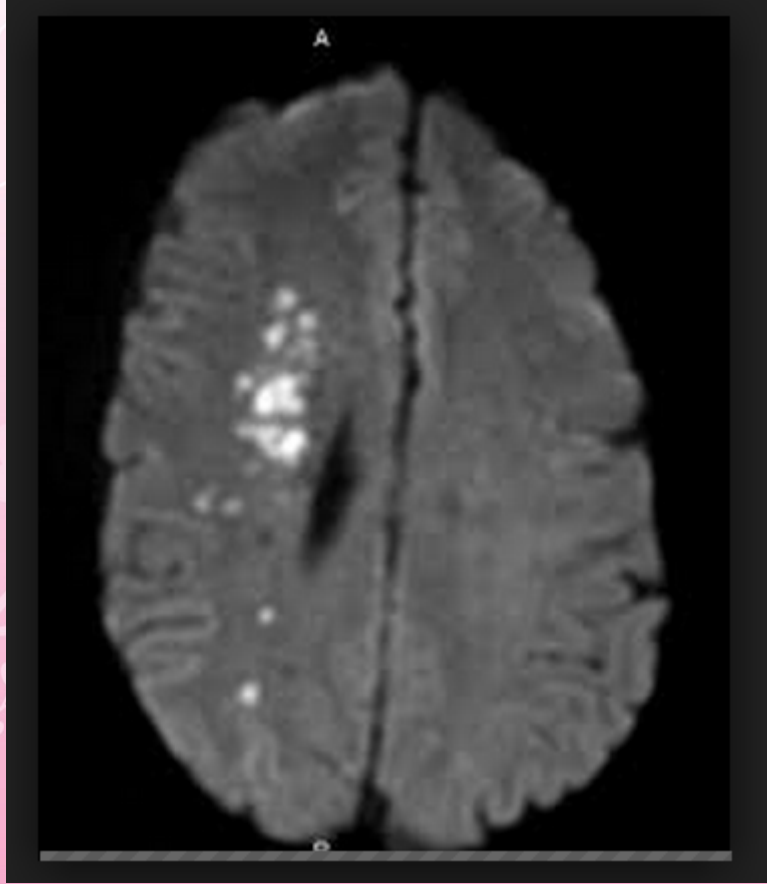


- 
- Watershed locations are those border-zone regions in the brain supplied by the major cerebral arteries where blood supply is decreased
  - Watershed strokes are a concern because they comprise approximately 10% of all ischaemic stroke cases

- 
- Watershed strokes are localized to two primary regions of the brain, and are termed
    1. cortical watersheds (CWS) and
    2. internal watersheds (IWS)






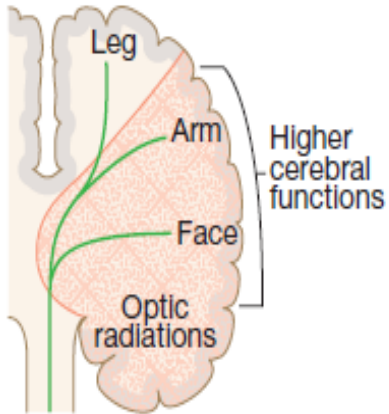
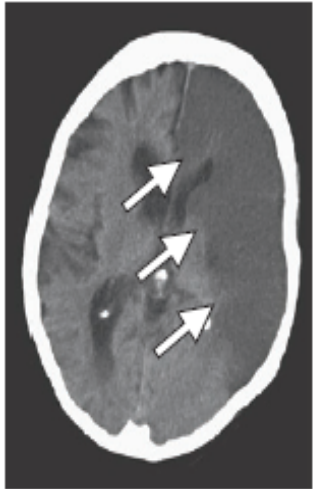
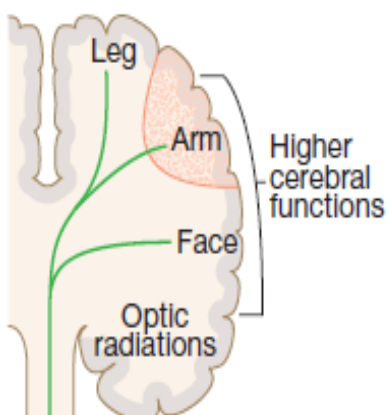



A decorative floral pattern in the top-left corner of the slide, featuring pink and white blossoms on thin branches.

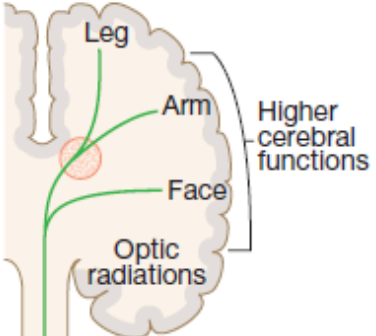
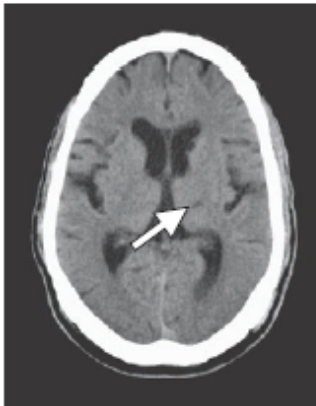
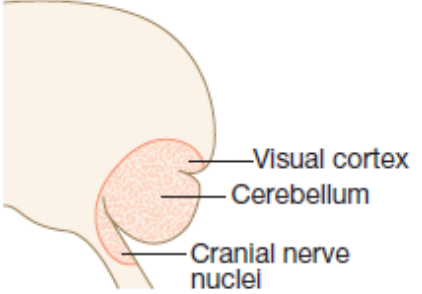
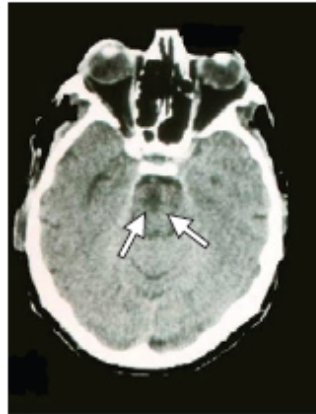
# Stroke Syndrome

- 
- Careful history and neurologic examination can often localize the region of brain dysfunction;
  - if this region corresponds to a particular arterial distribution, the possible causes responsible for the syndrome can be narrowed



| Clinical syndrome  | Common symptoms  | Common cause   | CT scan features   |
|--|--|--|--|
| <p>Total anterior circulation syndrome (TACS)</p>     | <p>Combination of:</p> <ul style="list-style-type: none"> <li>Hemiparesis</li> <li>Higher cerebral dysfunction (e.g. aphasia)</li> <li>Hemisensory loss</li> <li>Homonymous hemianopia (damage to optic radiations)</li> </ul>   | <p>Middle cerebral artery occlusion</p> <p>(Embolism from heart or major vessels)</p>  |   |
| <p>Partial anterior circulation syndrome (PACS)</p>  | <ul style="list-style-type: none"> <li>Isolated motor loss (e.g. leg only, arm only, face)</li> <li>Isolated higher cerebral dysfunction (e.g. aphasia, neglect)</li> <li>Mixture of higher cerebral dysfunction and motor loss (e.g. aphasia with right hemiparesis)</li> </ul> | <p>Occlusion of a branch of the middle cerebral artery or anterior cerebral artery</p> <p>(Embolism from heart or major vessels)</p> |  |



| Clinical syndrome  | Common symptoms   | Common cause  | CT scan features   |
|--|---|---|--|
| <p>Lacunar syndrome (LACS)</p>                              | <p>Pure motor stroke – affects two limbs</p> <p>Pure sensory stroke</p> <p>Sensory-motor stroke</p> <p>No higher cerebral dysfunction or hemianopia</p> | <p>Thrombotic occlusion of small perforating arteries</p> <p>(Thrombosis in situ)</p>   |   |
| <p>Posterior circulation stroke (POCS) (lateral view)</p>  | <p>Homonymous hemianopia (damage to visual cortex)</p> <p>Cerebellar syndrome</p> <p>Cranial nerve syndromes</p>  | <p>Occlusion in vertebral, basilar or posterior cerebral artery territory</p> <p>(Cardiac embolism or thrombosis in situ)</p> |  |

# Stroke

JOURNAL OF THE AMERICAN HEART ASSOCIATION



American Heart Association | American Stroke Association®

## **Guidelines for the Early Management of Patients With Acute Ischemic Stroke : A Guideline for Healthcare Professionals From the American Heart Association/American Stroke Association**


Edward C. Jauch, Jeffrey L. Saver, Harold P. Adams, Jr, Askiel Bruno, J.J. (Buddy) Connors, Bart M. Demaerschalk, Pooja Khatri, Paul W. McMullan, Jr, Adnan I. Qureshi, Kenneth Rosenfield, Phillip A. Scott, Debbie R. Summers, David Z. Wang, Max Wintermark and Howard Jonas

*Stroke*, published online January 31, 2013;

*Stroke* is published by the American Heart Association, 7272 Greenville Avenue, Dallas, TX 75231

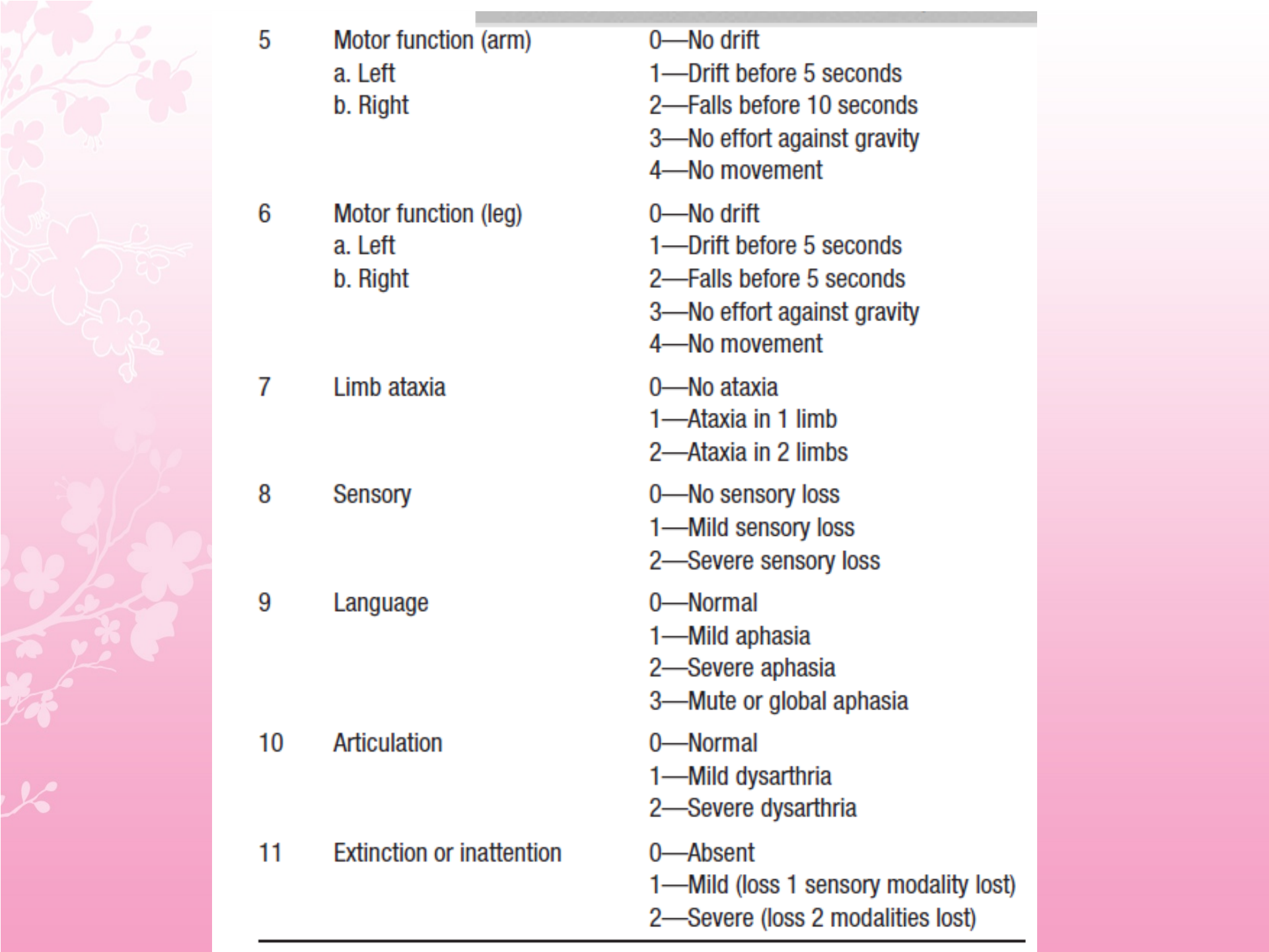
Copyright © 2013 American Heart Association, Inc. All rights reserved.

Print ISSN: 0039-2499. Online ISSN: 1524-4628

- 
- The use of a stroke rating scale, preferably the NIHSS, is recommended (*Class I; Level of Evidence B*)

**Table 7. National Institutes of Health Stroke Scale**

| Tested Item | Title                     | Responses and Scores  |
|-------------|---------------------------|---|
| 1A          | Level of consciousness    | 0—Alert<br>1—Drowsy<br>2—Obtunded<br>3—Coma/unresponsive  |
| 1B          | Orientation questions (2) | 0—Answers both correctly<br>1—Answers 1 correctly<br>2—Answers neither correctly                    |
| 1C          | Response to commands (2)  | 0—Performs both tasks correctly<br>1—Performs 1 task correctly<br>2—Performs neither                |
| 2           | Gaze                      | 0—Normal horizontal movements<br>1—Partial gaze palsy<br>2—Complete gaze palsy                      |
| 3           | Visual fields             | 0—No visual field defect<br>1—Partial hemianopia<br>2—Complete hemianopia<br>3—Bilateral hemianopia |
| 4           | Facial movement           | 0—Normal<br>1—Minor facial weakness<br>2—Partial facial weakness<br>3—Complete unilateral palsy     |

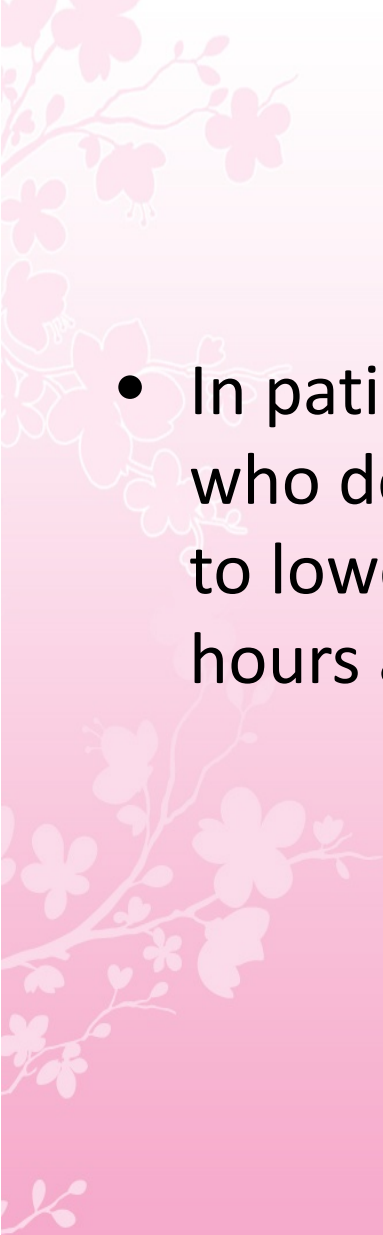


|    |   |   |
|----|---|---|
| 5  | Motor function (arm)<br>a. Left<br>b. Right | 0—No drift<br>1—Drift before 5 seconds<br>2—Falls before 10 seconds<br>3—No effort against gravity<br>4—No movement |
| 6  | Motor function (leg)<br>a. Left<br>b. Right | 0—No drift<br>1—Drift before 5 seconds<br>2—Falls before 5 seconds<br>3—No effort against gravity<br>4—No movement  |
| 7  | Limb ataxia                                 | 0—No ataxia<br>1—Ataxia in 1 limb<br>2—Ataxia in 2 limbs  |
| 8  | Sensory                                     | 0—No sensory loss<br>1—Mild sensory loss<br>2—Severe sensory loss   |
| 9  | Language                                    | 0—Normal<br>1—Mild aphasia<br>2—Severe aphasia<br>3—Mute or global aphasia  |
| 10 | Articulation                                | 0—Normal<br>1—Mild dysarthria<br>2—Severe dysarthria  |
| 11 | Extinction or inattention                   | 0—Absent<br>1—Mild (loss 1 sensory modality lost)<br>2—Severe (loss 2 modalities lost)                              |

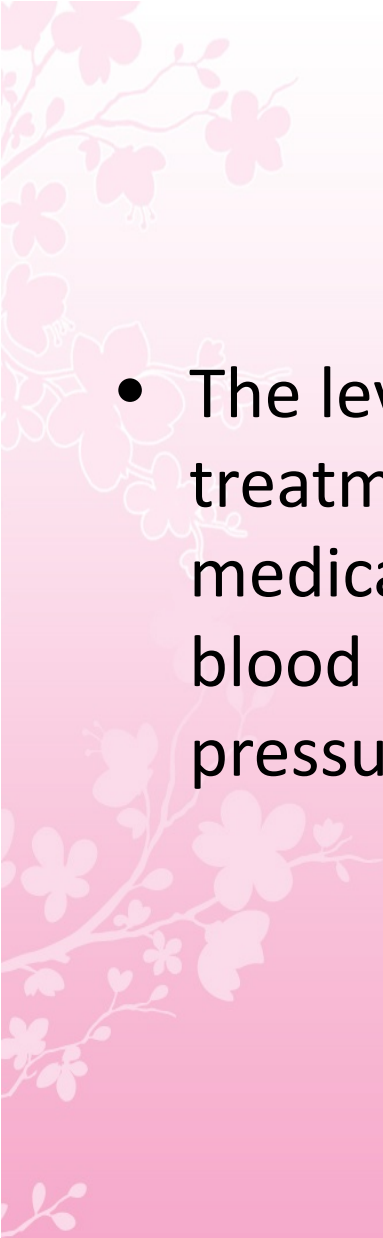
---

# General Supportive Care


- Sources of hyperthermia (temperature  $>38^{\circ}\text{C}$ ) should be identified and treated, and antipyretic medications should be administered to lower temperature in hyperthermic patients with stroke (*Class I; Level of Evidence C*)

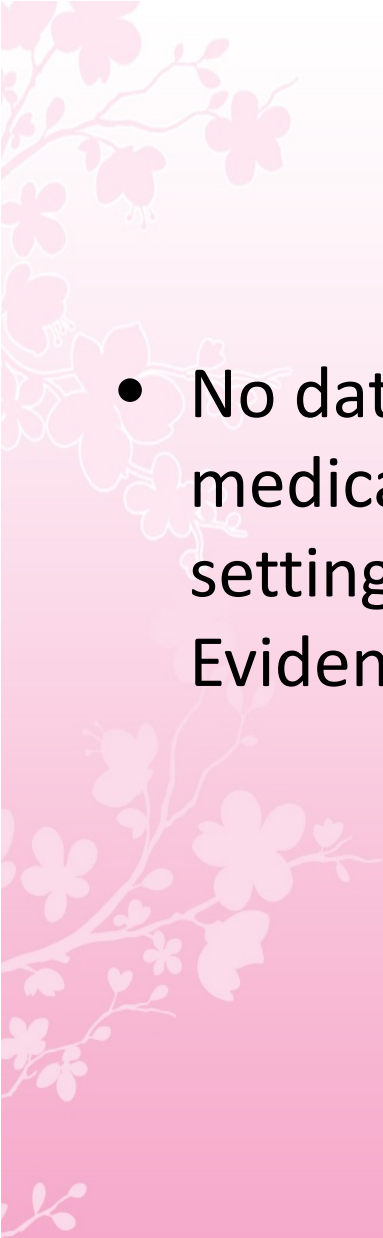
- 
- In patients with markedly elevated blood pressure who do not receive fibrinolysis, a reasonable goal is to lower blood pressure by 15% during the first 24 hours after onset of stroke.

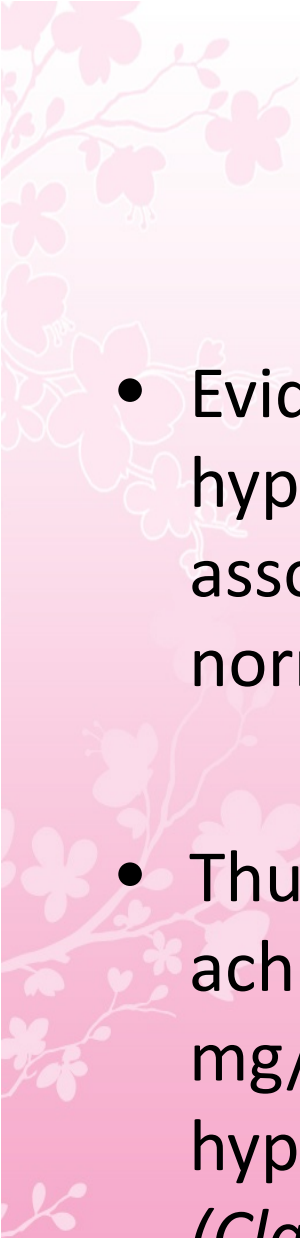



- 
- The level of blood pressure that would mandate such treatment is not known, but consensus exists that medications should be withheld unless the systolic blood pressure is  $>220$  mm Hg or the diastolic blood pressure is  $>120$  mm Hg (*Class I; Level of Evidence C*)

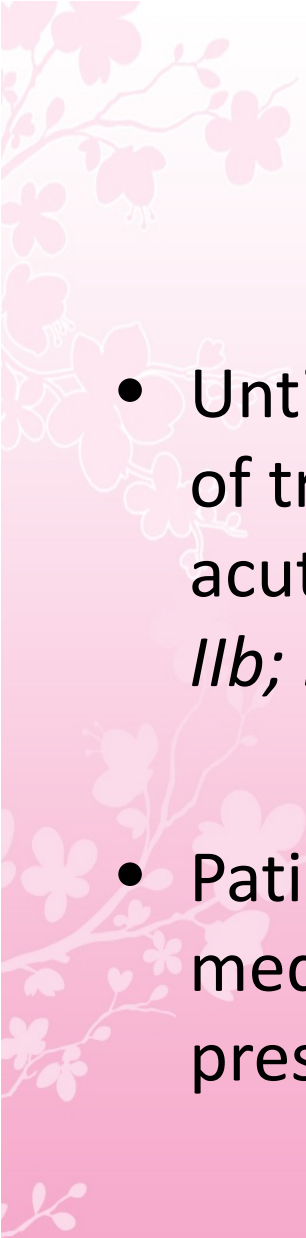



- 
- Evidence from one clinical trial indicates that initiation of antihypertensive therapy within 24 hours of stroke is relatively safe
  - Restarting antihypertensive medications is reasonable after the first 24 hours for patients who have preexisting hypertension and are neurologically stable unless a specific contraindication to restarting treatment is known (*Class IIa; Level of Evidence B*)

- 
- No data are available to guide selection of medications for the lowering of blood pressure in the setting of acute ischemic stroke (Class IIa; Level of Evidence C)

- 
- Evidence indicates that persistent in-hospital hyperglycemia during the first 24 hours after stroke is associated with worse outcomes than normoglycemia
  - Thus, it is reasonable to treat hyperglycemia to achieve blood glucose levels in a range of 140 to 180 mg/dL and to closely monitor to prevent hypoglycemia in patients with acute ischemic stroke  
*(Class IIa; Level of Evidence C)*

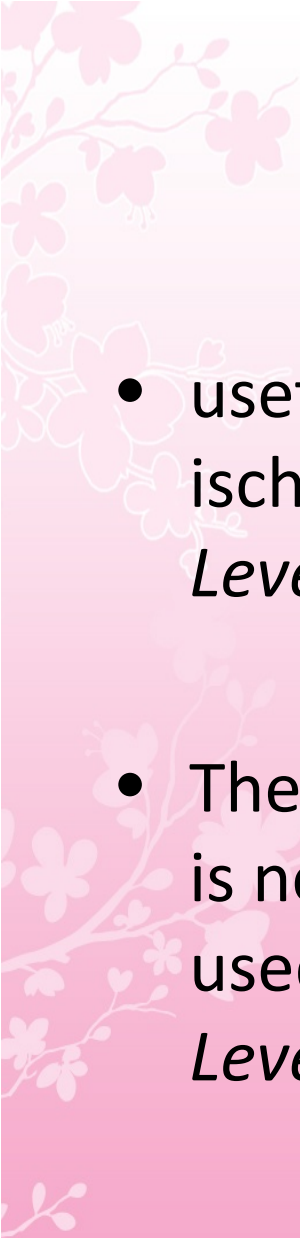
- 
- The management of arterial hypertension in patients not undergoing reperfusion strategies remains challenging.
  - Data to guide recommendations for treatment are inconclusive or conflicting.
  - Many patients have spontaneous declines in blood pressure during the first 24 hours after onset of stroke.

- 
- Until more definitive data are available, the benefit of treating arterial hypertension in the setting of acute ischemic stroke is not well established (*Class IIb; Level of Evidence C*)
  - Patients who have malignant hypertension or other medical indications for aggressive treatment of blood pressure should be treated accordingly


- 
- Supplemental oxygen is not recommended in nonhypoxic patients with acute ischemic stroke  
*(Class III; Level of Evidence B)*


# Antiplatelet Agents

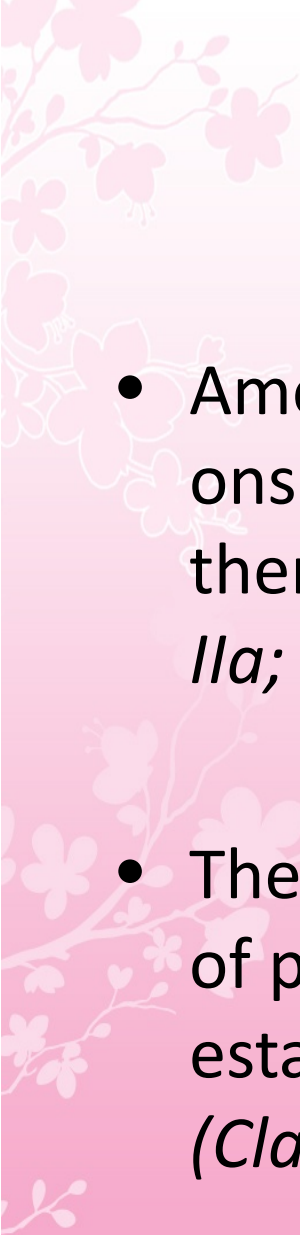
- Oral administration of aspirin (initial dose is 325 mg) within 24 to 48 hours after stroke onset is recommended for treatment of most patients (*Class I; Level of Evidence A*)

- 
- usefulness of clopidogrel for the treatment of acute ischemic stroke is not well established (*Class IIb; Level of Evidence C*)
  - The efficacy of intravenous tirofiban and eptifibatide is not well established, and these agents should be used only in the setting of clinical trials (*Class IIb; Level of Evidence C*)



- 
- Aspirin is not recommended as a substitute for other acute interventions for treatment of stroke, including intravenous rtPA (*Class III; Level of Evidence B*)
  - The administration of other intravenous antiplatelet agents that inhibit the glycoprotein IIb/IIIa receptor is not recommended (*Class III; Level of Evidence B*).

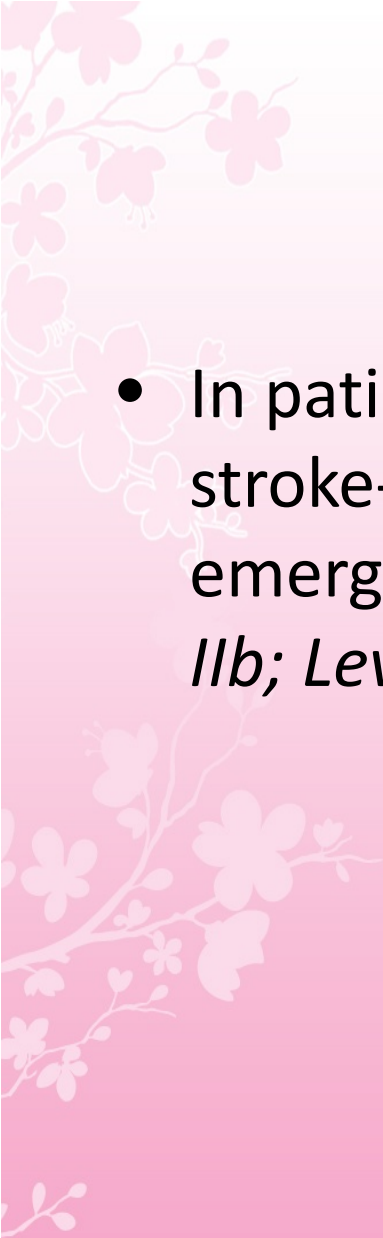
- 
- The administration of aspirin (or other antiplatelet agents) as an adjunctive therapy within 24 hours of intravenous fibrinolysis is not recommended (*Class III; Level of Evidence C*)

- 
- Among patients already taking statins at the time of onset of ischemic stroke, continuation of statin therapy during the acute period is reasonable (*Class IIa; Level of Evidence B*)
  - The utility of induced hypothermia for the treatment of patients with ischemic stroke is not well established, and further trials are recommended (*Class IIb; Level of Evidence B*)



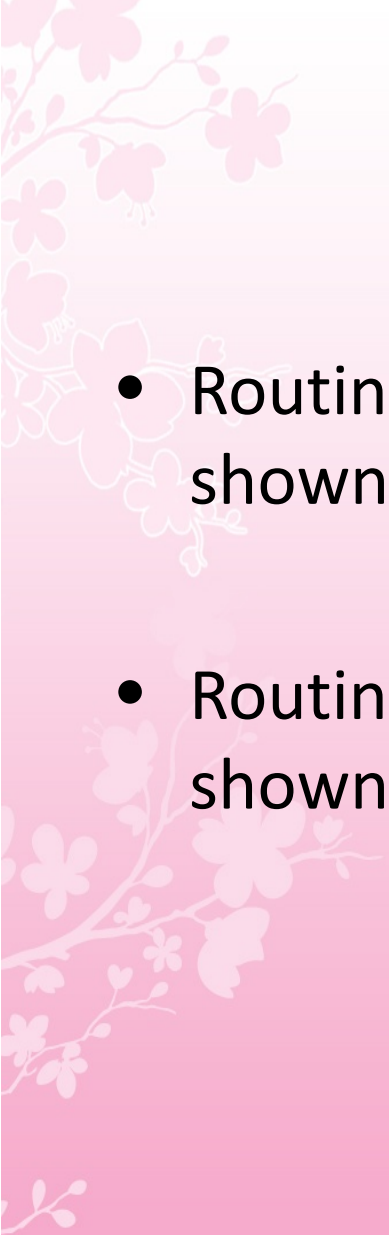
# Carotid Endarterectomy

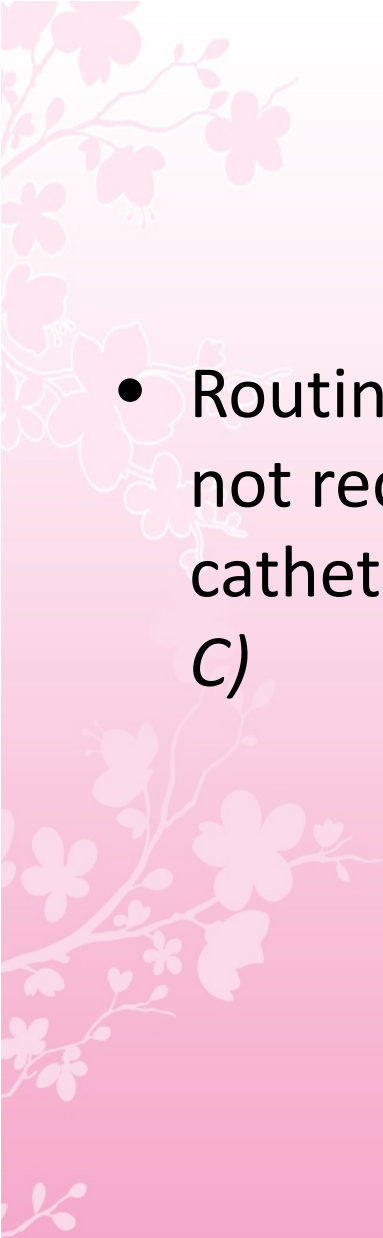
- The usefulness of emergent or urgent CEA when clinical indicators or brain imaging suggests a small infarct core with large territory at risk (eg, penumbra), compromised by inadequate flow from a critical carotid stenosis or occlusion, or in the case of acute neurological deficit after CEA, in which acute thrombosis of the surgical site is suspected, is not well established (*Class IIb; Level of Evidence B*)

- 
- In patients with unstable neurological status (either stroke-in-evolution or crescendo TIA), the efficacy of emergent or urgent CEA is not well established (*Class IIb; Level of Evidence B*)

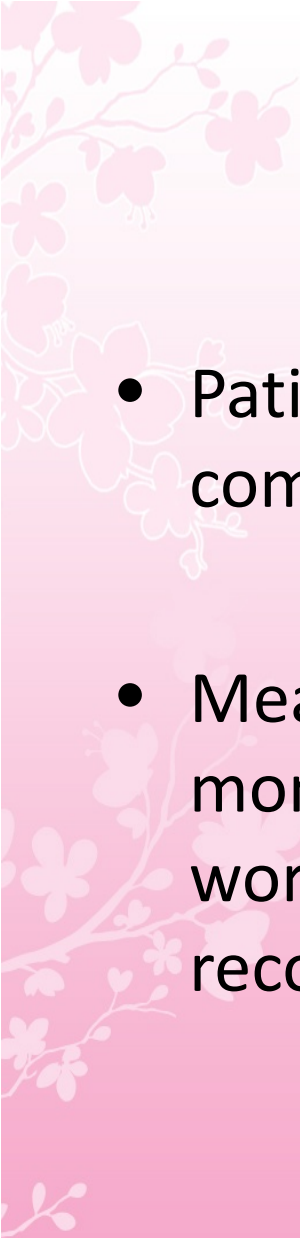
# General Stroke Care

- Assessment of swallowing before the patient begins eating, drinking, or receiving oral medications is recommended (*Class I; Level of Evidence B*)
- In selecting between NG and PEG tube routes of feeding in patients who cannot take solid food or liquids orally, it is reasonable to prefer NG tube feeding until 2 to 3 weeks after stroke onset (*Class IIa; Level of Evidence B*)

- 
- Routine use of nutritional supplements has not been shown to be beneficial (*Class III; Level of Evidence B*)
  - Routine use of prophylactic antibiotics has not been shown to be beneficial (*Class III; Level of Evidence B*)

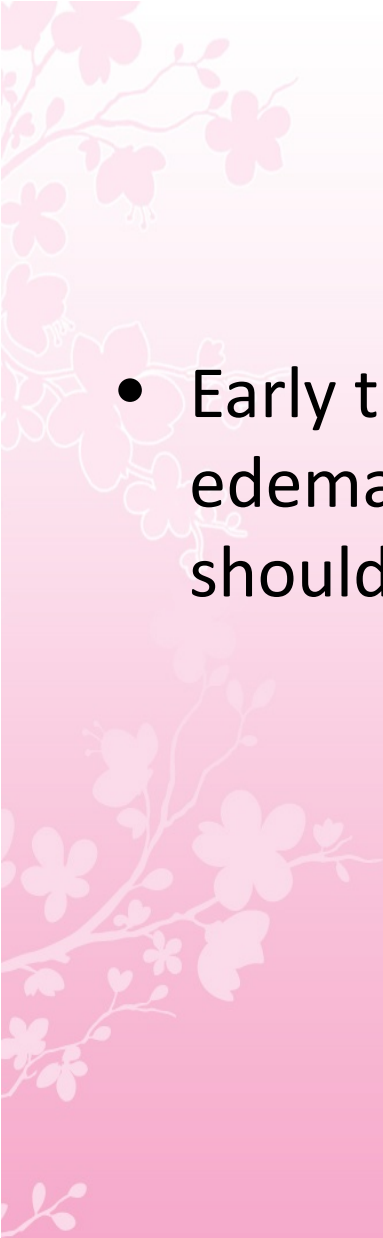
- 
- Routine placement of indwelling bladder catheters is not recommended because of the associated risk of catheter-associated UTIs (*Class III; Level of Evidence C*)




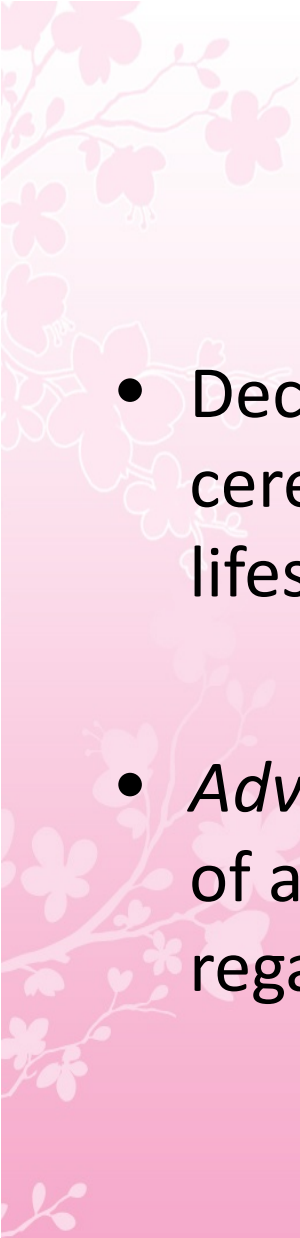


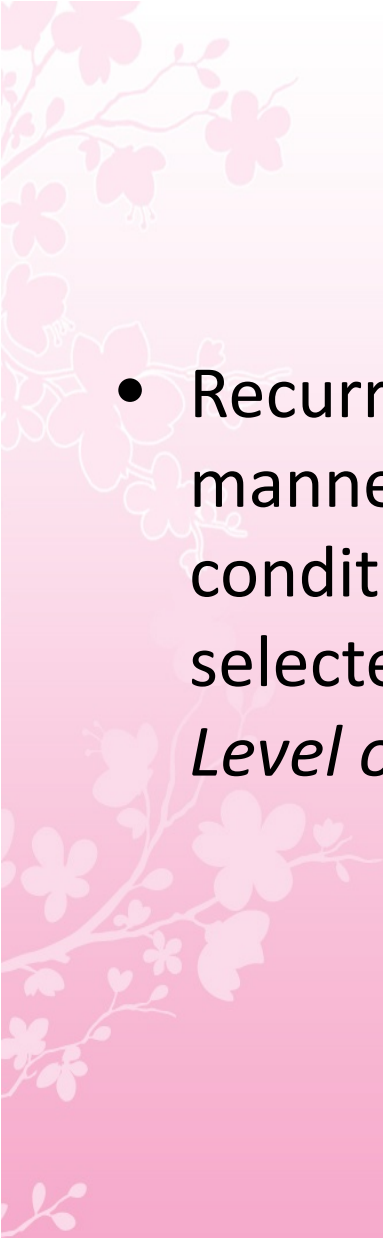
# Treatment of Acute Neurological Complications

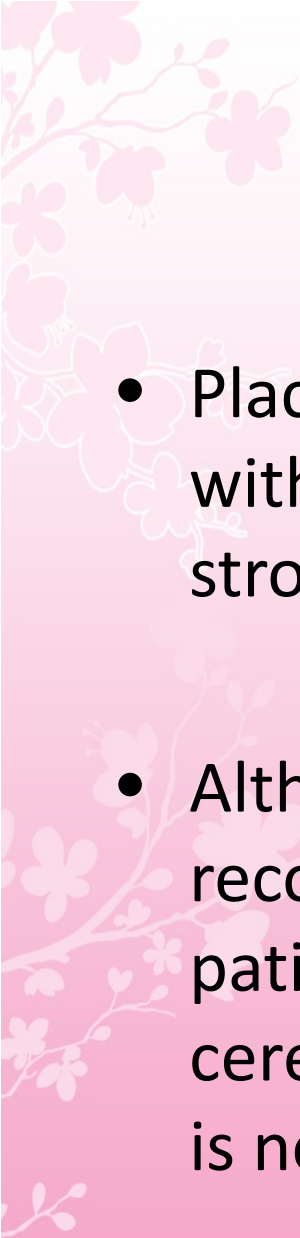
- Patients with major infarctions are at high risk for complicating brain edema and increased ICP.
- Measures to lessen the risk of edema and close monitoring of the patient for signs of neurological worsening during the first days after stroke are recommended (*Class I; Level of Evidence A*).

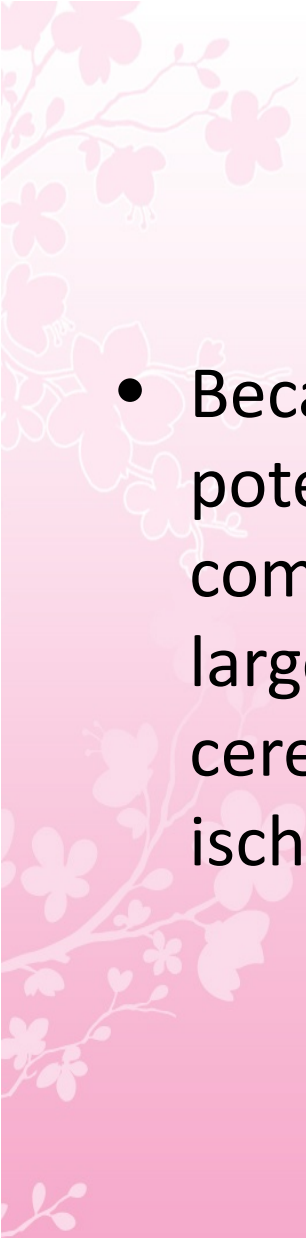
- 
- Early transfer of patients at risk for malignant brain edema to an institution with neurosurgical expertise should be considered


- 
- Decompressive surgical evacuation of a space-occupying cerebellar infarction is effective in preventing and treating herniation and brain stem compression (*Class I; Level of Evidence B*)

- 
- Decompressive surgery for malignant edema of the cerebral hemisphere is effective and potentially lifesaving (*Class I; Level of Evidence B*)
  - *Advanced* patient age and patient/family valuations of achievable outcome states may affect decisions regarding surgery

- 
- Recurrent seizures after stroke should be treated in a manner similar to other acute neurological conditions, and antiepileptic agents should be selected by specific patient characteristics (*Class I; Level of Evidence B*)

- 
- Placement of a ventricular drain is useful in patients with acute hydrocephalus secondary to ischemic stroke (*Class I; Level of Evidence C*)
  - Although aggressive medical measures have been recommended for treatment of deteriorating patients with malignant brain edema after large cerebral infarction, the usefulness of these measures is not well established (*Class IIb; Level of Evidence C*).


- 
- Because of lack of evidence of efficacy and the potential to increase the risk of infectious complications, corticosteroids (in conventional or large doses) are not recommended for treatment of cerebral edema and increased ICP complicating ischemic stroke (*Class III; Level of Evidence A*)

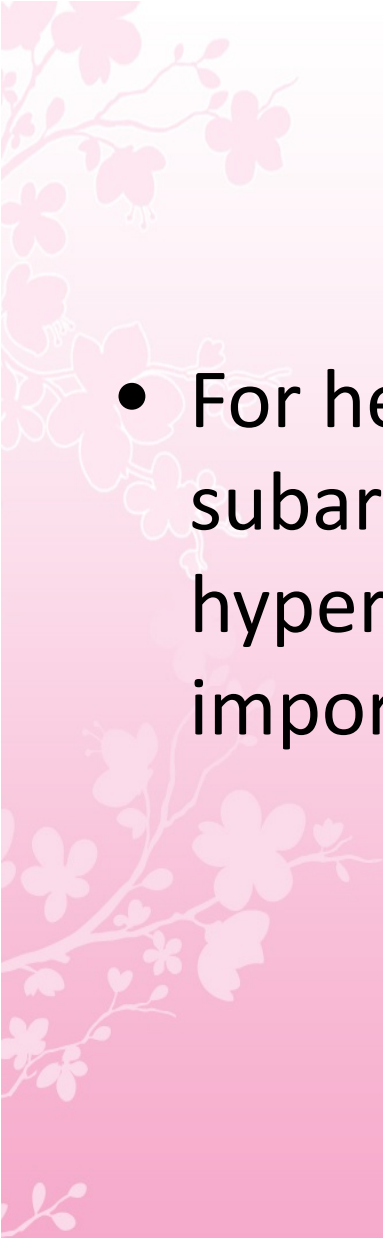
- 
- Prophylactic use of anticonvulsants is not recommended (*Class III; Level of Evidence C*)





# Intracranial Hemorrhage

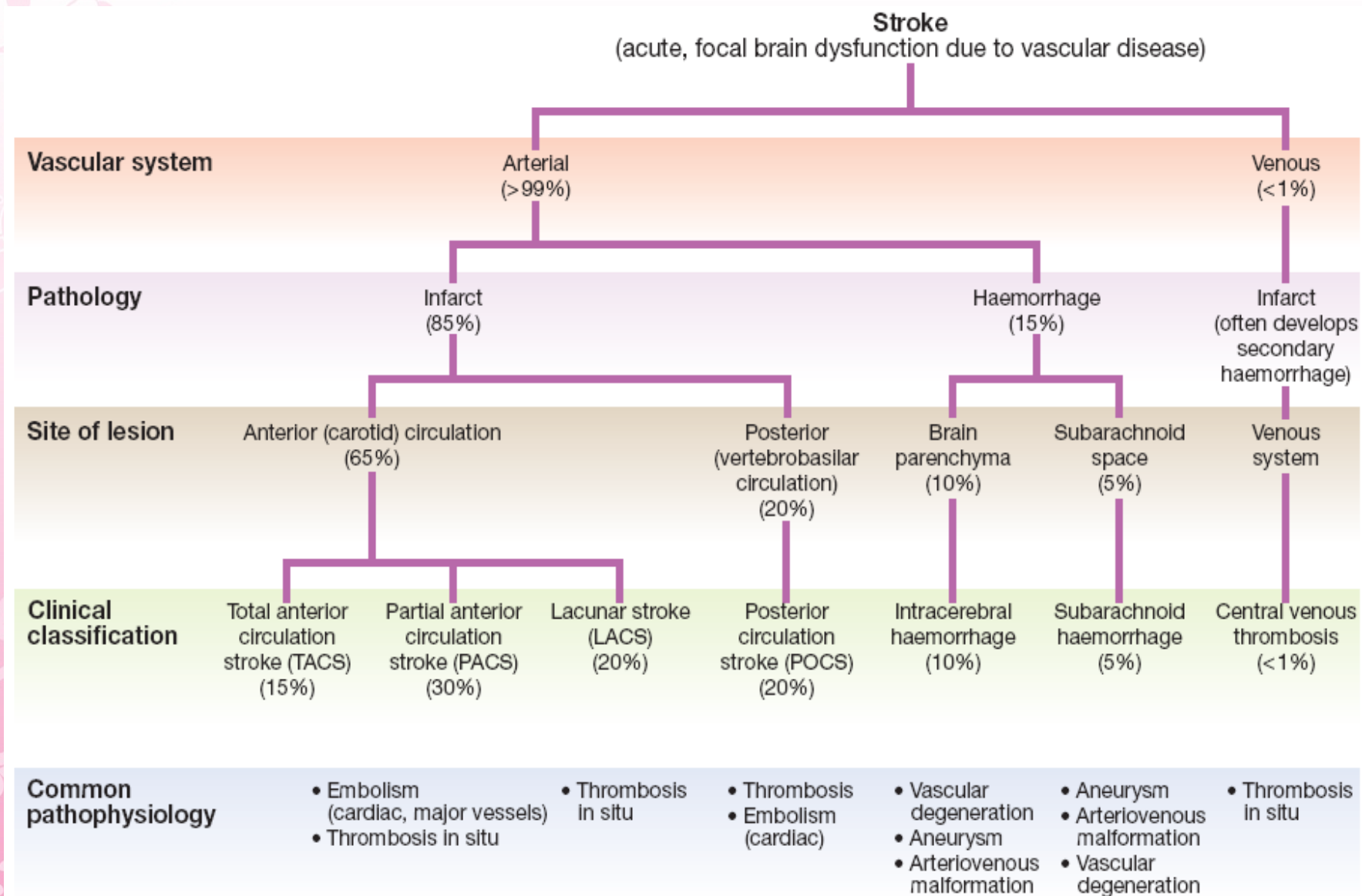
- 
- *Intracranial hemorrhage* is caused by bleeding directly into or around the brain;
  - it produces neurologic symptoms by producing a mass effect on neural structures, from the toxic effects of blood itself, or by increasing intracranial pressure

- 
- For hemorrhagic stroke, aneurysmal subarachnoid hemorrhage (SAH) and hypertensive intracranial hemorrhage are two important causes

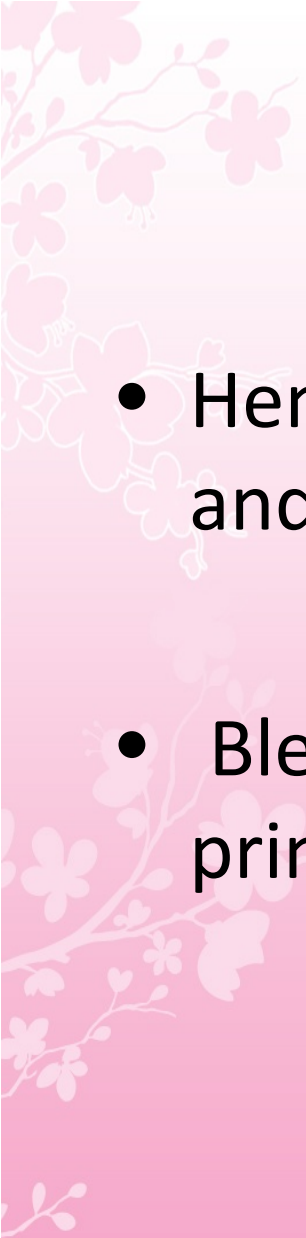


## 27.2 Causes of intracerebral haemorrhage and associated risk factors

| Disease  | Risk factors   |
|--|--|
| <b>Complex small-vessel disease with disruption of vessel wall</b> | Age<br>Hypertension<br>High cholesterol                          |
| <b>Amyloid angiopathy</b>  | Familial (rare)<br>Age   |
| <b>Impaired blood clotting</b>                                     | Anticoagulant therapy<br>Blood dyscrasia<br>Thrombolytic therapy |
| <b>Vascular anomaly</b>  | Arteriovenous malformation<br>Cavernous haemangioma              |
| <b>Substance misuse</b>  | Alcohol<br>Amphetamines<br>Cocaine                               |




**Fig. 27.1** A classification of stroke disease.

- 
- Hemorrhages are classified by their location and the underlying vascular pathology
  - Bleeding into subdural and epidural spaces is principally produced by trauma

**Table 370-6 Causes of Intracranial Hemorrhage**

| Cause                                       | Location   | Comments   |
|---|--|--|
| Head trauma                                 | Intraparenchymal: frontal lobes, anterior temporal lobes; subarachnoid | Coup and contrecoup injury during brain deceleration   |
| Hypertensive hemorrhage                     | Putamen, globus pallidus, thalamus, cerebellar hemisphere, pons        | Chronic hypertension produces hemorrhage from small (~100 $\mu$ m) vessels in these regions              |
| Transformation of prior ischemic infarction | Basal ganglion, subcortical regions, lobar                             | Occurs in 1–6% of ischemic strokes with predilection for large hemispheric infarctions                   |
| Metastatic brain tumor                      | Lobar  | Lung, choriocarcinoma, melanoma, renal cell carcinoma, thyroid, atrial myxoma                            |
| Coagulopathy                                | Any  | Uncommon cause; often associated with prior stroke or underlying vascular anomaly                        |
| Drug  | Lobar, subarachnoid  | Cocaine, amphetamine, phenylpropanolamine  |
| Arteriovenous malformation                  | Lobar, intraventricular, subarachnoid                                  | Risk is ~2–4% per year for bleeding  |
| Aneurysm                                    | Subarachnoid, intraparenchymal, rarely subdural                        | Mycotic and nonmycotic forms of aneurysms  |
| Amyloid angiopathy                          | Lobar  | Degenerative disease of intracranial vessels; linkage to Alzheimer's disease, rare in patients <60 years |
| Cavernous angioma                           | Intraparenchymal   | Multiple cavernous angiomas linked to mutations in KRIT1, CCM2, and PDCD10 genes                         |
| Dural arteriovenous fistula                 | Lobar, subarachnoid  | Produces bleeding by venous hypertension   |
| Capillary telangiectasias                   | Usually brainstem  | Rare cause of hemorrhage   |

- 
- SAHs are produced by trauma and rupture of intracranial aneurysms
  - Intraparenchymal and intraventricular hemorrhage will be considered here







## Diagnosis


- Intracranial hemorrhage is often discovered on noncontrast CT imaging of the brain during the acute evaluation of stroke
- Since CT is more sensitive than routine MRI for acute blood, CT imaging is the preferred method for acute stroke evaluation

A decorative floral pattern in the top-left corner of the slide, featuring pink and white blossoms on thin branches.

# Intraparenchymal Hemorrhage

- 
- ICH is the most common type of intracranial hemorrhage
  - It accounts for 10% of all strokes and is associated with a 50% case fatality rate
  - Incidence rates are particularly high in Asians and blacks


- 
- Hypertension, trauma, and cerebral amyloid angiopathy cause the majority of these hemorrhages
  - Advanced age and heavy alcohol consumption increase the risk, and cocaine and methamphetamine use is one of the most important causes in the young

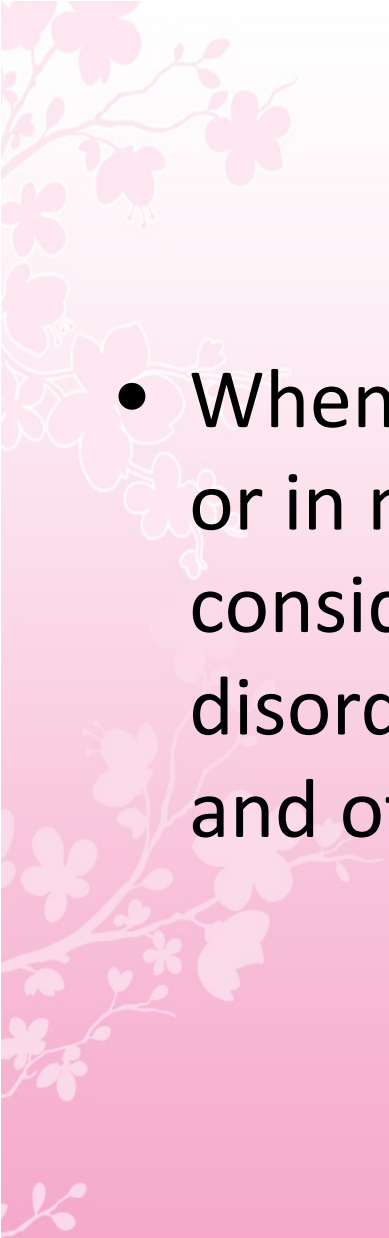


# Hypertensive Intraparenchymal Hemorrhage


# Pathophysiology

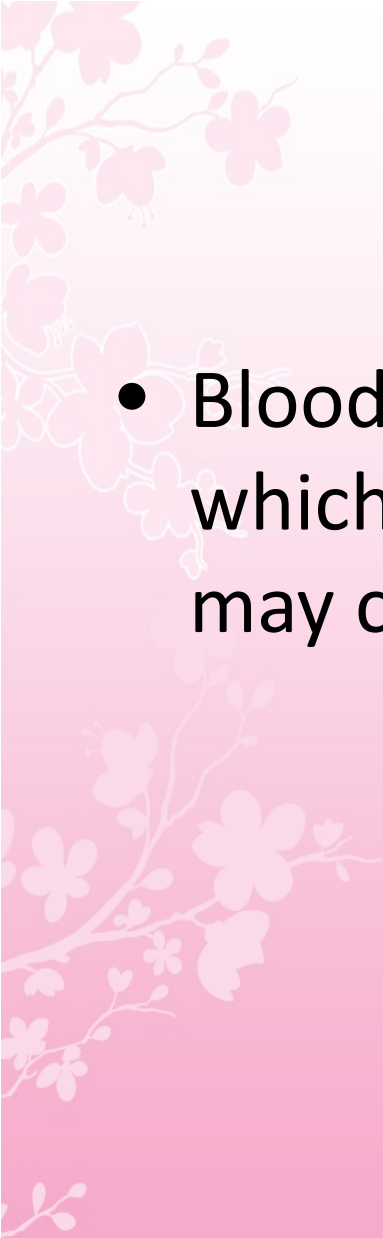
- Hypertensive intraparenchymal hemorrhage (hypertensive hemorrhage or hypertensive intracerebral hemorrhage) usually results from spontaneous rupture of a small penetrating artery deep in the brain

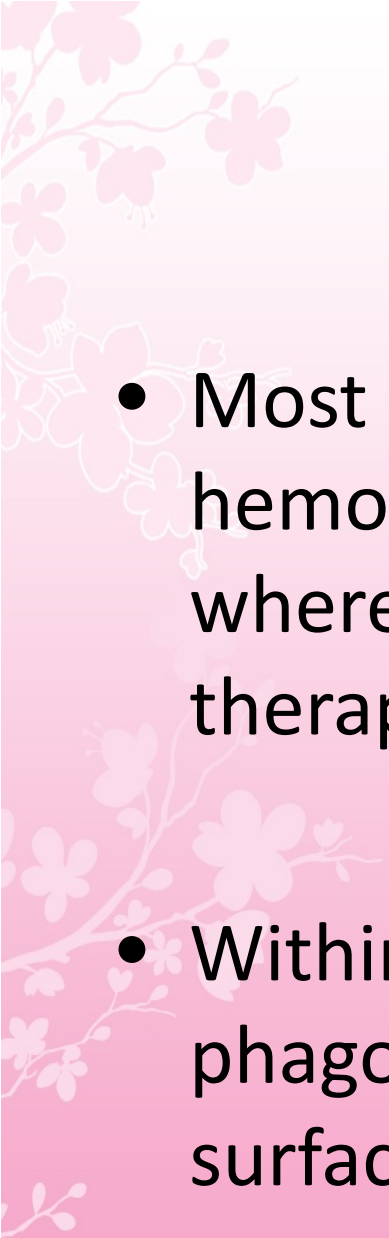
- 
- The most common sites are the basal ganglia (especially the putamen), thalamus, cerebellum, and pons


- 
- When hemorrhages occur in other brain areas or in nonhypertensive patients, greater consideration should be given to hemorrhagic disorders, neoplasms, vascular malformations, and other causes



- 
- The small arteries in these areas seem most prone to hypertension-induced vascular injury
  - The hemorrhage may be small or a large clot may form and compress adjacent tissue, causing herniation and death


- 
- Blood may dissect into the ventricular space, which substantially increases morbidity and may cause hydrocephalus


- 
- Most hypertensive intraparenchymal hemorrhages develop over 30–90 minutes, whereas those associated with anticoagulant therapy may evolve for as long as 24–48 hours
  - Within 48 hours macrophages begin to phagocytize the hemorrhage at its outer surface

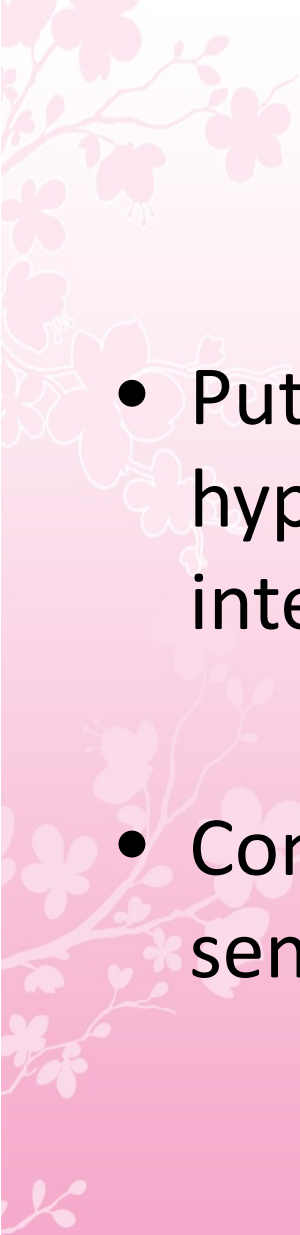
- 
- After 1–6 months, the hemorrhage is generally resolved to a slitlike orange cavity lined with glial scar and hemosiderin-laden macrophages

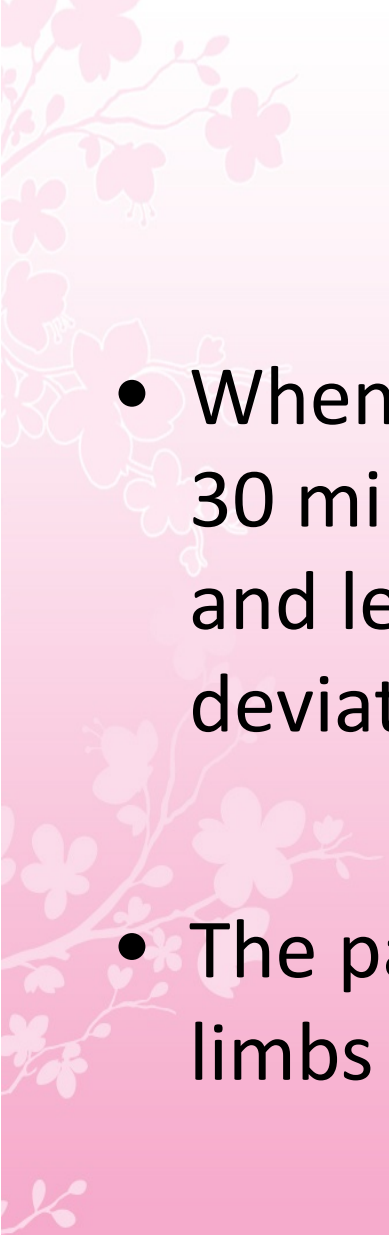


# Clinical Manifestations

- The hemorrhage generally presents as the abrupt onset of focal neurologic deficit
  - Seizures are uncommon
- 

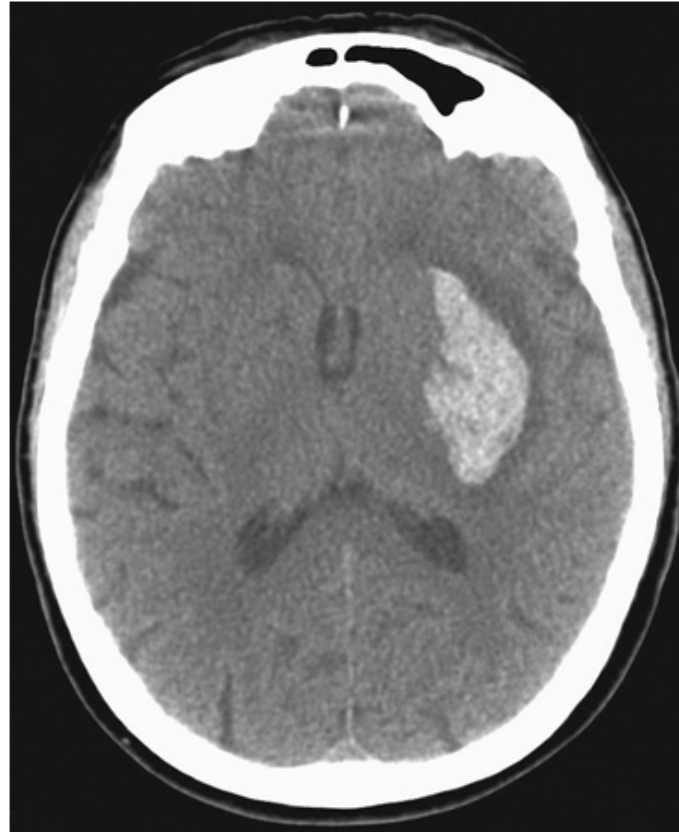- 
- The focal deficit typically worsens steadily over 30–90 minutes and is associated with a diminishing level of consciousness and signs of increased ICP such as headache and vomiting

- 
- Putamen is the most common site for hypertensive hemorrhage, and the adjacent internal capsule is usually damaged
  - Contralateral hemiparesis is therefore the sentinel sign


- 
- When mild, the face sags on one side over 5–30 minutes, speech becomes slurred, the arm and leg gradually weaken, and the eyes deviate away from the side of the hemiparesis
  - The paralysis may worsen until the affected limbs become flaccid or extend rigidly




**Hypertensive hemorrhage.** Transaxial noncontrast CT scan through the region of the basal ganglia reveals a hematoma involving the left putamen in a patient with rapidly progressive onset of right hemiparesis.




Source: Longo DL, Fauci AS, Kasper DL, Hauser SL, Jameson JL, Loscalzo J: *Harrison's Principles of Internal Medicine, 18th Edition*: [www.accessmedicine.com](http://www.accessmedicine.com)  
Copyright © The McGraw-Hill Companies, Inc. All rights reserved.

- 
- When hemorrhages are large, drowsiness gives way to stupor as signs of upper brainstem compression appear

- 
- Coma ensues, accompanied by deep, irregular, or intermittent respiration, a dilated and fixed ipsilateral pupil, and decerebrate rigidity
  - In milder cases, edema in adjacent brain tissue may cause progressive deterioration over 12–72 hours

# Thalamic hemorrhage


- **Thalamic hemorrhage** also produce a contralateral hemiplegia or hemiparesis from pressure on, or dissection into, the adjacent internal capsule

- 
- Thalamic hemorrhages cause several typical ocular disturbances by virtue of extension inferiorly into the upper midbrain



These include

- deviation of the eyes downward and inward so that they appear to be looking at the nose, unequal pupils with absence of light reaction,
- skew deviation with the eye opposite the hemorrhage displaced downward and medially,
- ipsilateral Horner's syndrome,
- absence of convergence, paralysis of vertical gaze, and retraction nystagmus

- 
- Patients may later develop a chronic, contralateral pain syndrome (Déjérine-Roussy syndrome).

# Pontine Hemorrhage

In pontine hemorrhages,

- deep coma with quadriplegia usually occurs over a few minutes
- There is often prominent decerebrate rigidity and "pinpoint" (1 mm) pupils that react to light



# Pontine Hemorrhage

- There is impairment of reflex horizontal eye movements evoked by head turning (doll's-head or oculocephalic maneuver) or by irrigation of the ears with ice water

# Pontine Hemorrhage

- Hyperpnea, severe hypertension, and hyperhidrosis are common
- Death often occurs within a few hours, but small hemorrhages are compatible with survival

# Cerebellar Hemorrhage

- Cerebellar hemorrhages usually develop over several hours and are characterized by occipital headache, repeated vomiting, and ataxia of gait
- In mild cases there may be no other neurologic signs other than gait ataxia
- Dizziness or vertigo may be prominent



# Cerebellar Hemorrhage

- Dysarthria and dysphagia may occur
- As the hours pass, the patient often becomes stuporous and then comatose from brainstem compression or obstructive hydrocephalus
- immediate surgical evacuation before brainstem compression occurs may be lifesaving.

# Cerebellar Hemorrhage

- Hydrocephalus from fourth ventricle compression can be relieved by external ventricular drainage, but definitive hematoma evacuation is essential for survival
- If the deep cerebellar nuclei are spared, full recovery is common



# Lobar Hemorrhage

- Symptoms and signs appear over several minutes
- Most lobar hemorrhages are small and cause a restricted clinical syndrome that simulates an embolus to an artery supplying one lobe

# Lobar Hemorrhage

- For example, the major neurologic deficit with an occipital hemorrhage is hemianopia; with a left temporal hemorrhage, aphasia and delirium; with a parietal hemorrhage, hemisensory loss; and with frontal hemorrhage, arm weakness



# Lobar Hemorrhage

- Large hemorrhages may be associated with stupor or coma if they compress the thalamus or midbrain
- Most patients with lobar hemorrhages have focal headaches, and more than one-half vomit or are drowsy
- Stiff neck and seizures are uncommon



# Treatment: Intracerebral Hemorrhage

## Acute Management

- Nearly 50% of patients with a hypertensive ICH die, but others have a good to complete recovery if they survive the initial hemorrhage



# Acute Management

- Any identified coagulopathy should be reversed as soon as possible
- For patients taking VKAs, rapid reversal of coagulopathy can be achieved by infusing prothrombin complex concentrates which can be administered quickly, followed by fresh-frozen plasma and vitamin K

# Acute Management

- When ICH is associated with thrombocytopenia (platelet count  $<50,000/L$ ), transfusion of fresh platelets is indicated
- The role of urgent platelet inhibition assays in the decision to transfuse platelets remains unclear

# Acute Management

- Hematomas may expand for several hours following the initial hemorrhage, so treating severe hypertension seems reasonable to prevent hematoma progression

# Acute Management

- For cerebellar hemorrhages, a neurosurgeon should be consulted immediately to assist with the evaluation; most cerebellar hematomas  $>3$  cm in diameter will require surgical evacuation

# Acute Management

- If the patient is alert without focal brainstem signs and if the hematoma is  $<1$  cm in diameter, surgical removal is usually unnecessary



# Acute Management

- Patients with hematomas between 1 and 3 cm require careful observation for signs of impaired consciousness and precipitous respiratory failure

# Acute Management

- Tissue surrounding hematomas is displaced and compressed but not necessarily infarcted
- Hence, in survivors, major improvement commonly occurs as the hematoma is reabsorbed and the adjacent tissue regains its function

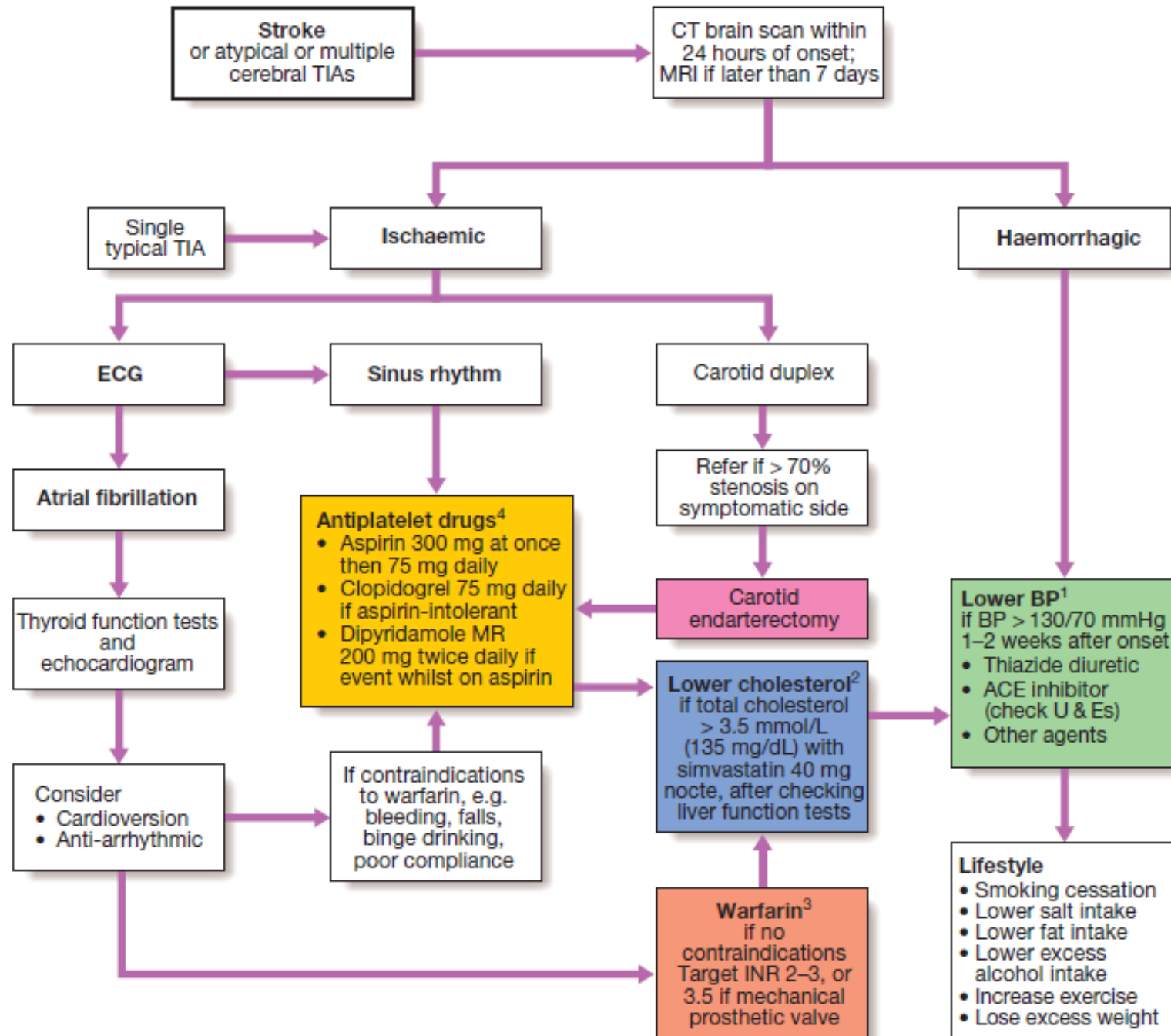


# Acute Management

- Careful management of the patient during the acute phase of the hemorrhage can lead to considerable recovery

# Prevention

- Hypertension is the leading cause of primary ICH
- Prevention is aimed at reducing hypertension, eliminating excessive alcohol use, and discontinuing use of illicit drugs such as cocaine and amphetamines





**THANK YOU**